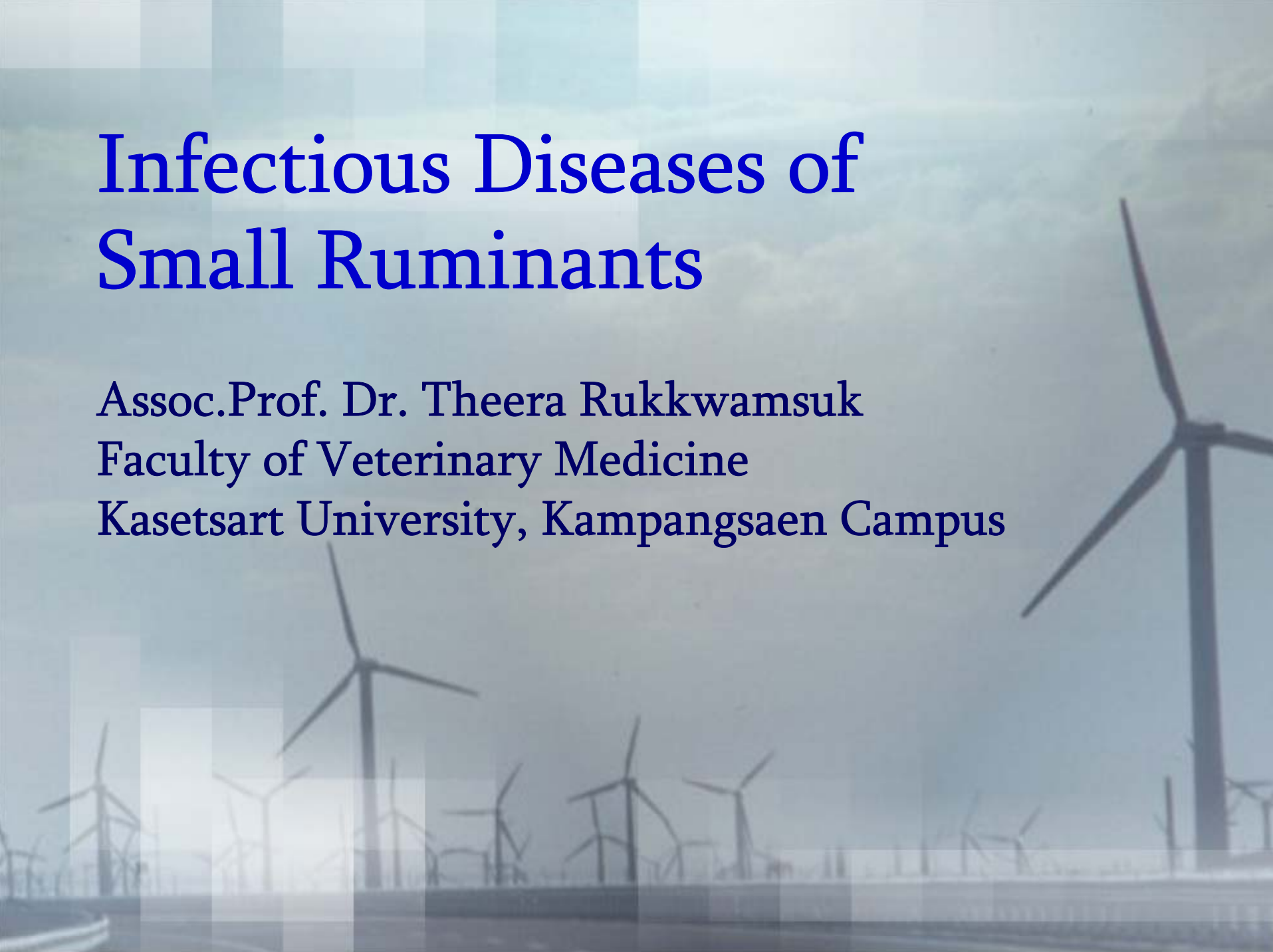

Infectious Diseases of Small Ruminants

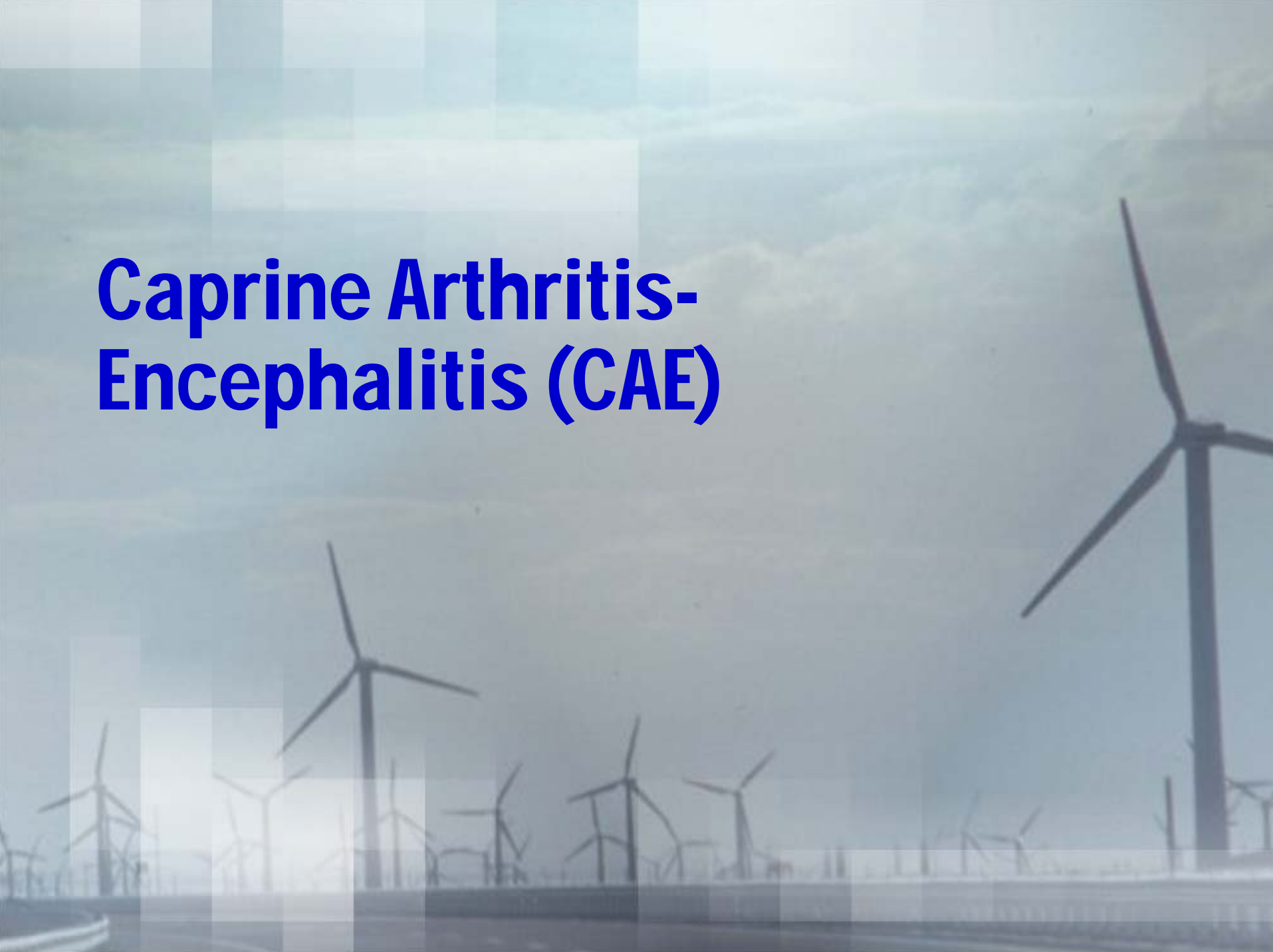Assoc.Prof. Dr. Theera Rukkwamsuk
Faculty of Veterinary Medicine
Kasetsart University, Kamphaengsaen Campus



Infectious diseases of small ruminants

- Caprine arthritis-encephalitis (CAE)
- Caseous lymphadenitis (CLA)
- Tuberculosis
- Paratuberculosis
- Lymphosarcoma
- Footrot
- Infectious keratoconjunctivitis (pinkeye)

Caprine Arthritis- Encephalitis (CAE)

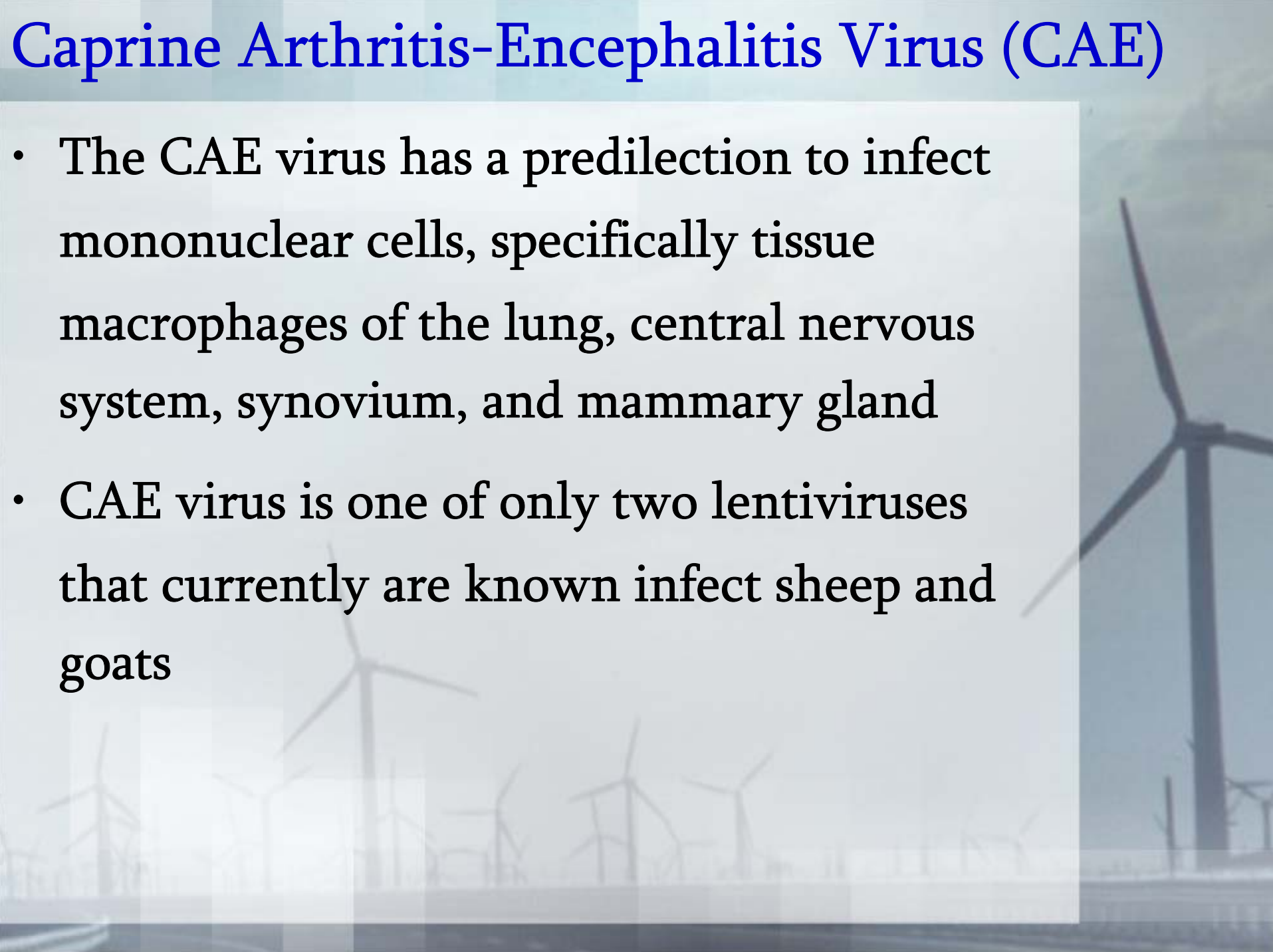


Caprine Arthritis-Encephalitis Virus (CAE)

- Caprine arthritis-encephalitis virus (CAE) is a single-stranded, icosahedral, RNA virus of the family *Retroviridae* and the sub-family *Lentivirinae*
- Infection with CAE results in a persistent, lifelong infection
- This disease was first diagnosed in goats in 1974

Caprine Arthritis-Encephalitis Virus (CAE)

- The CAE virus has a predilection to infect mononuclear cells, specifically tissue macrophages of the lung, central nervous system, synovium, and mammary gland
- CAE virus is one of only two lentiviruses that currently are known infect sheep and goats



Caprine Arthritis-Encephalitis Virus (CAE)

- CAE viral infection results in arthritis in adult animals and encephalitis in kids between 2 and 6 months of age
- Other clinical presentations can include a hard udder or mastitis, hypogalactia, chronic interstitial pneumonia, and progressive weight loss

Goat with CAE infection



Etiology

- The prevalence of CAE, first known as viral leukoencephalomyelitis of goats, is highest where there is intensive dairy goat management in confinement
- Countries with the highest prevalence of CAE infection include the United States, France, Norway, Switzerland, and Canada
- Viral transmission usually occurs horizontally through the ingestion of viral-infected goat milk and/or goat colostrum

Etiology

- Other potential sources of viral transmission include transmission *in utero*; contact with the vagina of an infected doe during parturition; via saliva or respiratory secretions; via contact with infected blood; viral contamination of milking equipment, needles, tattooing equipment; and breeding an infected animal with a non-infected animal

Pathogenesis

- CAE virus infects goats primarily by horizontal transmission via ingestion of infected colostrum or infected milk
- The virus is absorbed across the small intestine and infects the mononuclear cells
- There is also transmission of CAE virus by direct contact between goats via shedding of the virus in the saliva, the urogenital secretions, and the feces

Pathogenesis

- Contact with the blood of an infected animal can also transmit the disease
- CAE virus remains latent until the monocytes mature into macrophages
- macrophages then disseminate to other tissues such as mammary gland, choroid plexus, synovium, lung interstitium, and their associated draining lymph nodes

Pathogenesis

- Clinical signs and lesions of CAE are associated with the viral replication in the infected macrophages
- Active viral infection induces a strong, but non-protective, humoral and cell mediated immune response
- It is also important to note that the maternal antibodies passed in the colostrum are not protective for kids ingesting the colostrum

Pathogenesis

- Recent research has shown that lentiviruses can develop a tropism for and replicate within epithelial cells
- Caprine oviduct epithelial cells (COEC) are often utilized from untested slaughterhouse animals to aid *in vitro* fertilization techniques
- embryo transfer also may be a possible mode of transmission for CAE

Clinical signs

- Most goats infected with CAE virus are asymptomatic, but there are five major clinical presentations associated with viral infection including arthritis, encephalitis, interstitial pneumonia, mastitis, and progressive weight loss
- The arthritic form of CAE viral infection is the most common manifestation of the disease and is generally observed in sexually mature goats (6 months and older)

Clinical signs

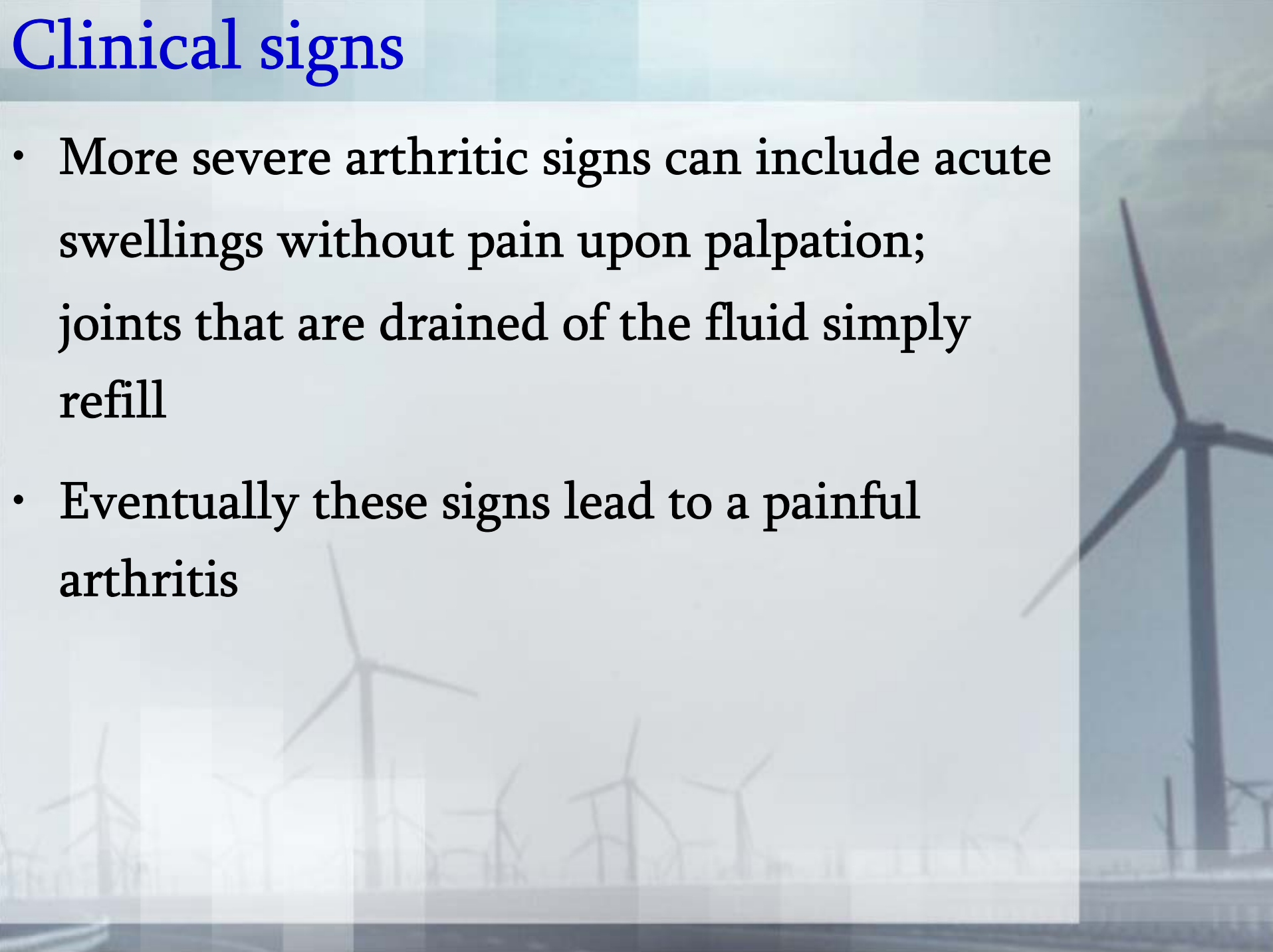
- The arthritis tends to be chronic and progressive, though there have been reports of a sudden onset of lameness
- Joints that are commonly affected (in descending prevalence) include: carpal joints, tarsal joints, stifle joints, fetlock joints, alantooccipital joint, and coxofemoral joints

Clinical signs

- All synovial membranes can be affected by CAE virus, and the number of joints affected in any one animal can vary. Early arthritic signs may be subtle or severe
- Subtle signs include stiffness, shifting leg lameness, decreased ambulation, weight loss, reluctance to rise, and abnormal posture after rising

Clinical signs

- More severe arthritic signs can include acute swellings without pain upon palpation; joints that are drained of the fluid simply refill
- Eventually these signs lead to a painful arthritis

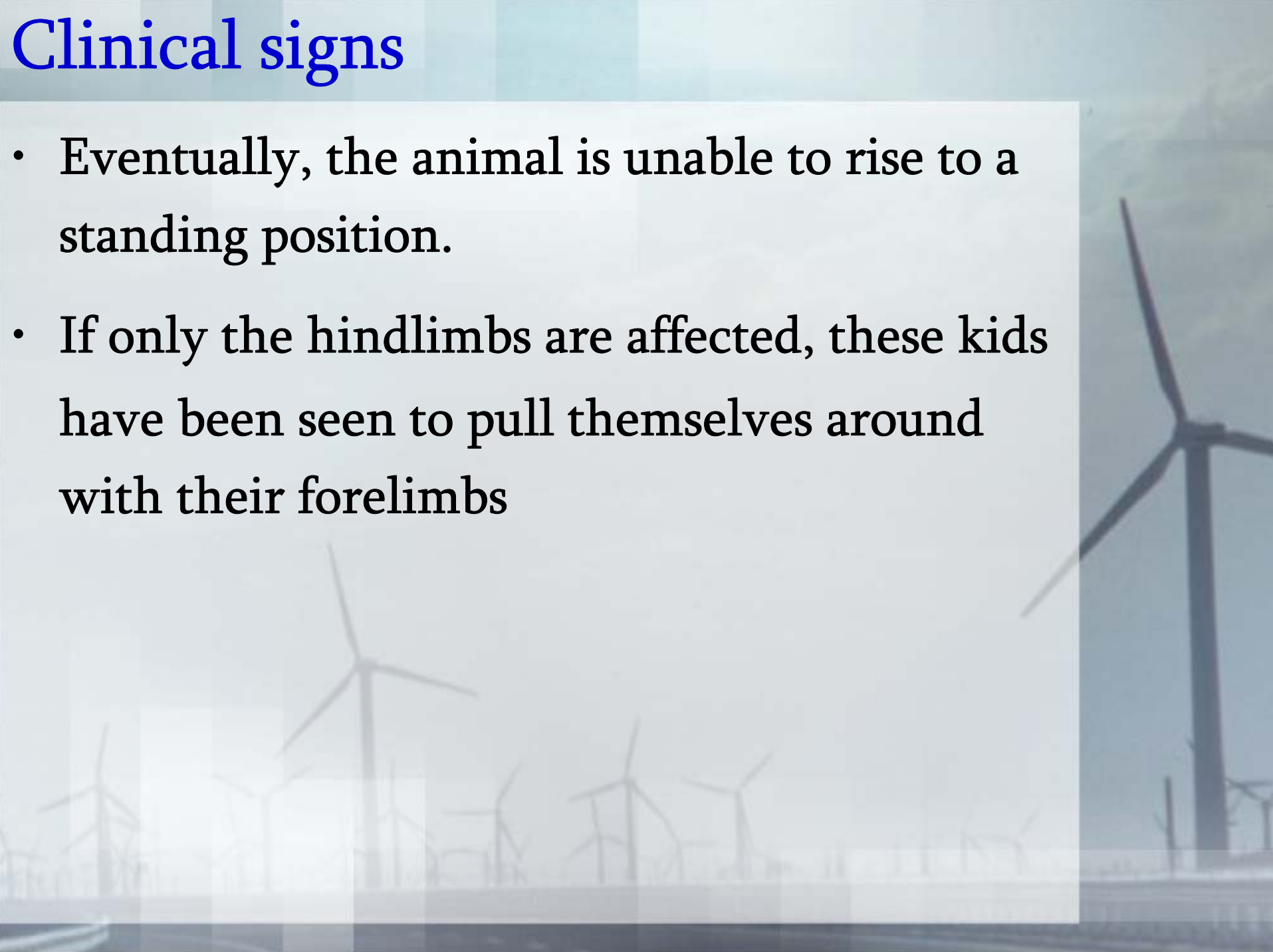


Clinical signs

- The encephalitic form of CAE viral infection most commonly affects kids between 2 and 6 months of age
- The kids may show incoordination and inappropriate placement of limbs while standing and walking
- A gradual paresis and paralysis, more commonly affecting the hindlimbs and often progressing to the forelimbs, can occur

Clinical signs

- Eventually, the animal is unable to rise to a standing position.
- If only the hindlimbs are affected, these kids have been seen to pull themselves around with their forelimbs



Clinical signs

- The kids can remain bright, alert, and responsive early in the disease process, but more commonly display additional neurologic deficits including depression, nystagmus, abnormal pupillary response, blindness, head tilt, head tremor, dysphagia, torticollis, circling, and facial nerve deficits
- Affected kids are afebrile unless a secondary disease present

Clinical signs

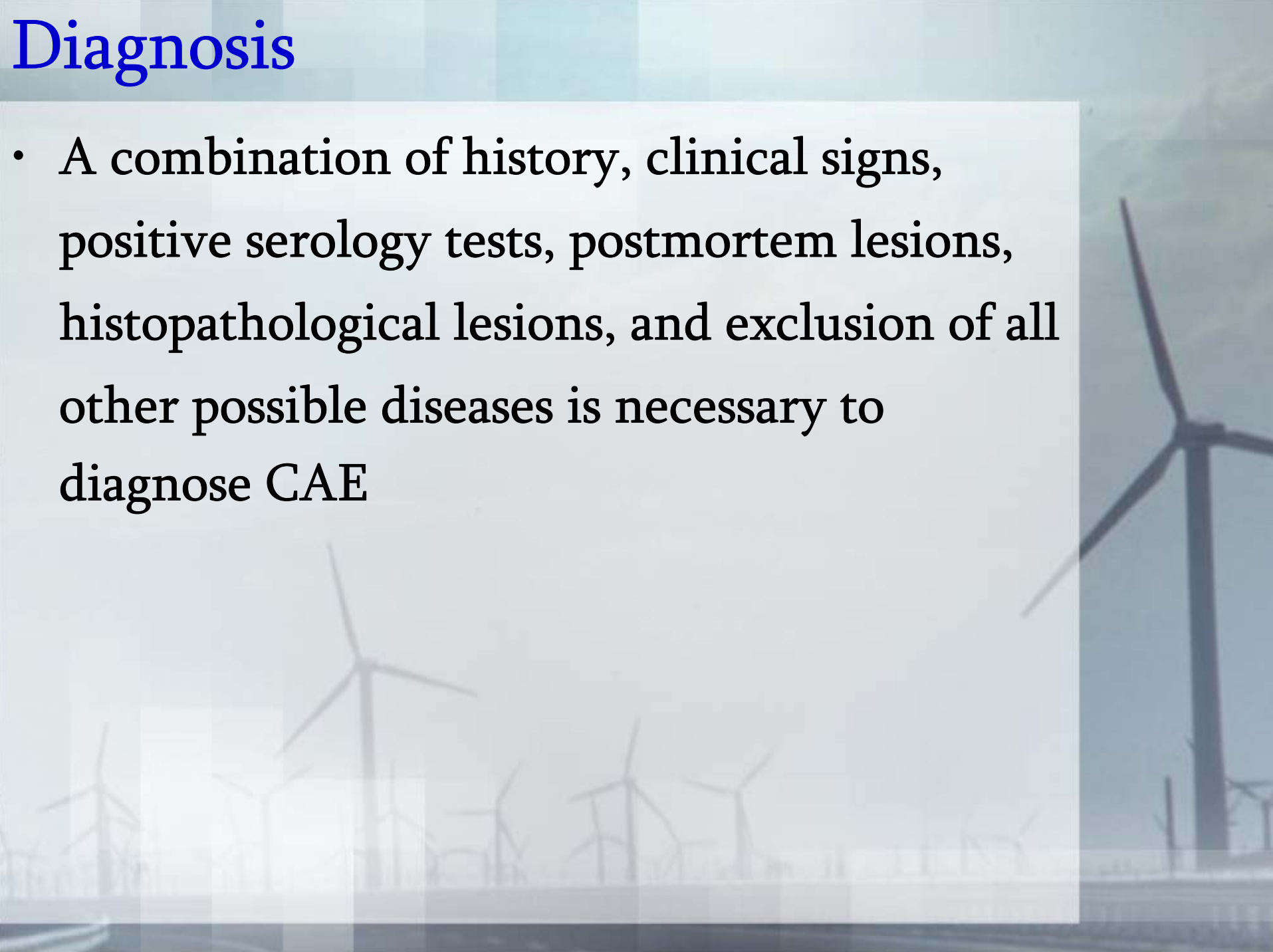
- CAE viral infection also can cause chronic interstitial pneumonia
- Initially, a deep chronic cough can be observed. Later, chronic dyspnea, weight loss, tachypnea, and abnormal lung sounds can develop
- It has also been noted that enlarged lymph nodes may contribute to some of the respiratory distress

Clinical signs

- Mastitis, especially interstitial mastitis, is another form of CAE. Clinical signs include a firm, distended udder from which milk cannot be expressed. The mastitis usually is observed around parturition
- The final major form of CAE viral infection is chronic progressive weight loss.
- The progressive weight loss also can occur with any of the other forms of the disease

Diagnosis

- A combination of history, clinical signs, positive serology tests, postmortem lesions, histopathological lesions, and exclusion of all other possible diseases is necessary to diagnose CAE

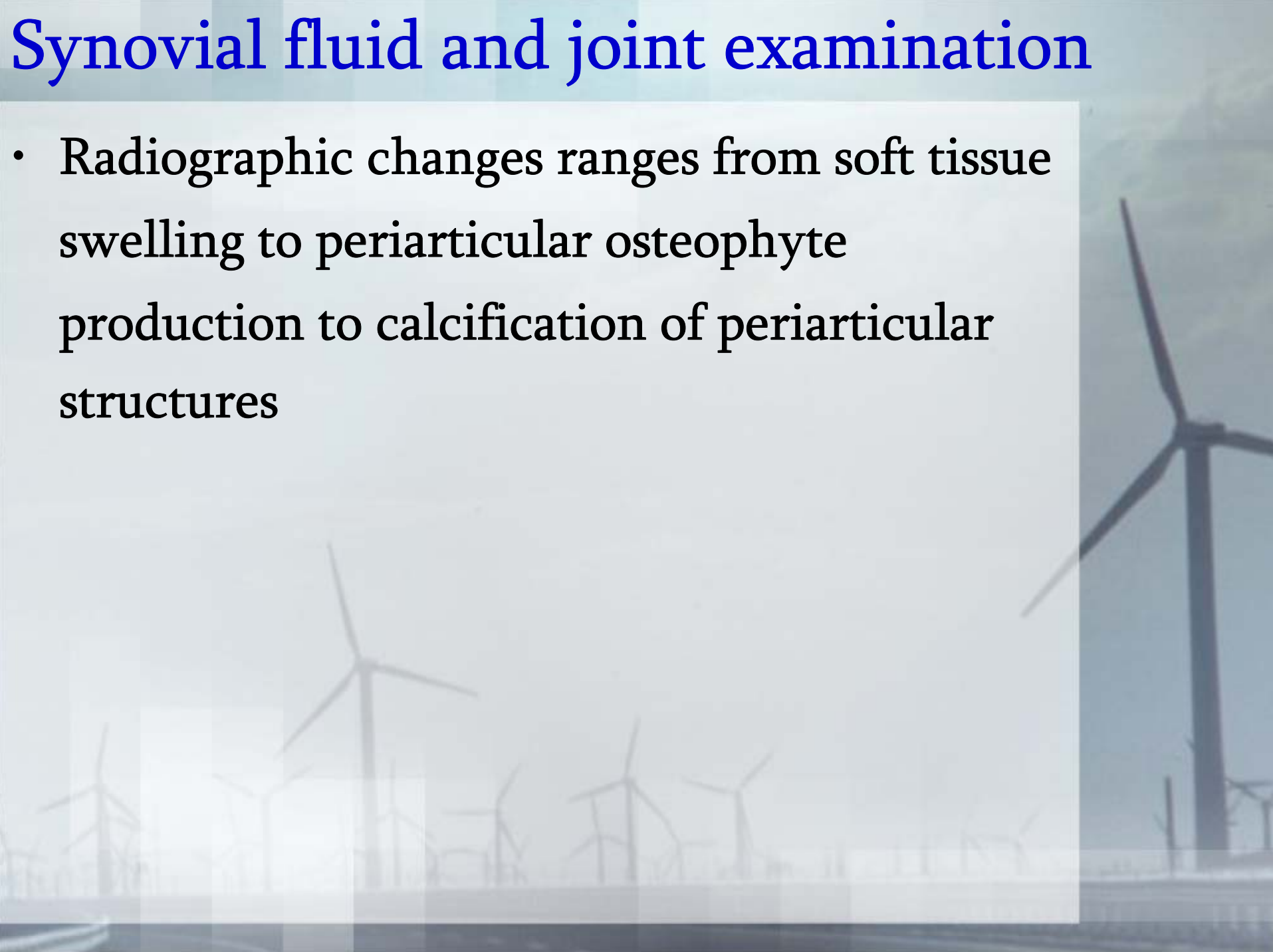


Synovial fluid and joint examination

- In CAE-associated arthritis, arthrocentesis may reveal synovial fluid that is serous and has a dark yellow to red-brown color
- The fluid also contains an increased number of lymphocytes and macrophages (mononuclear cells)
- The nucleated cell counts in the synovial fluid are $> 1,000$ cells / μl , and the predominant cell type is the lymphocyte

Synovial fluid and joint examination

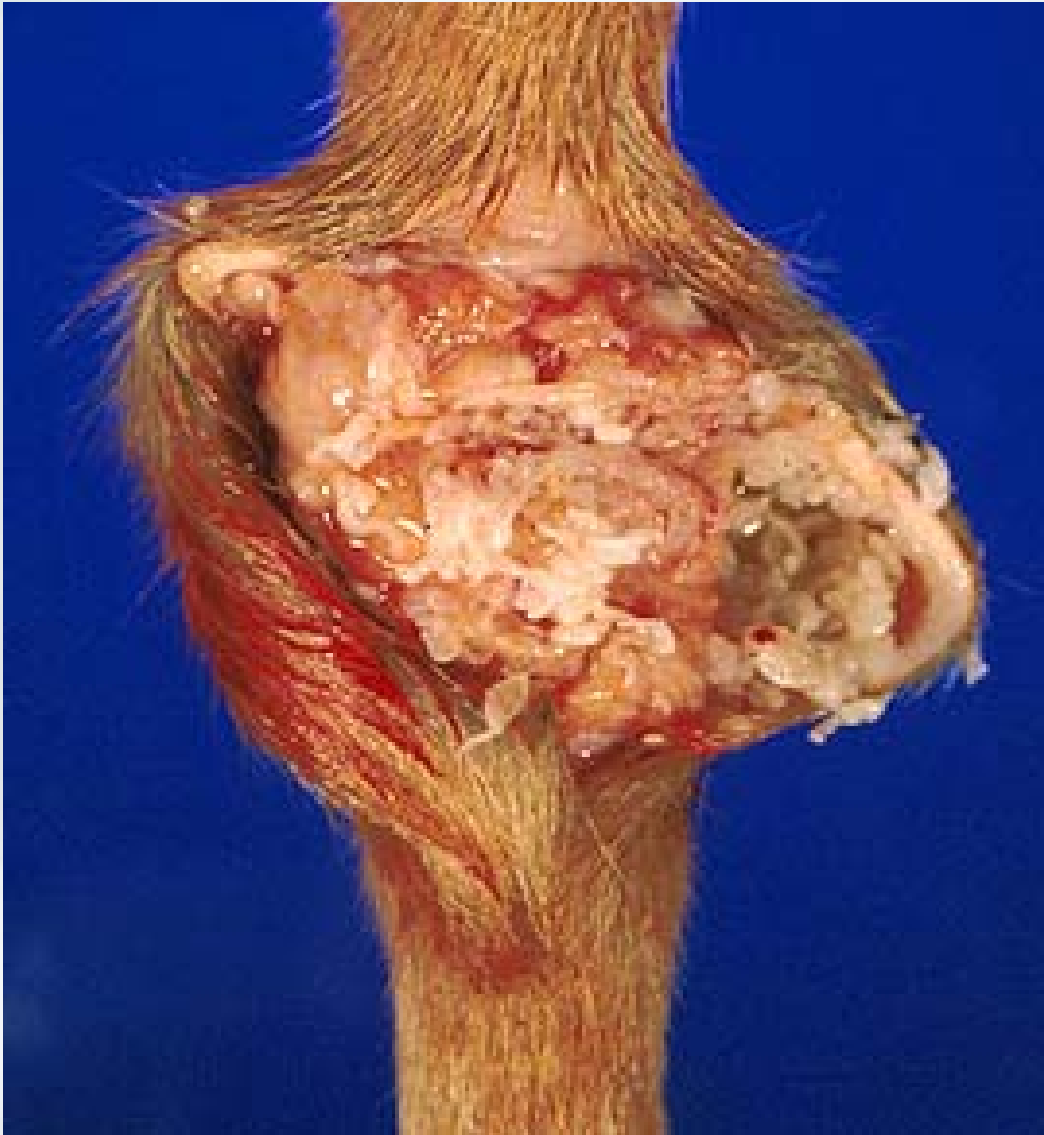- Radiographic changes ranges from soft tissue swelling to periarticular osteophyte production to calcification of periarticular structures



Synovial fluid and joint examination

- During post-mortem examination of the joints, marked proliferation of the synovial lining (pannus), extensive osteophyte formation, free floating concretions (rice bodies or joint mice), degenerative joint disease with destruction of subchondral bone, ulceration and erosion of articular cartilages, and mineralization of surrounding tissues of the joint can be observed

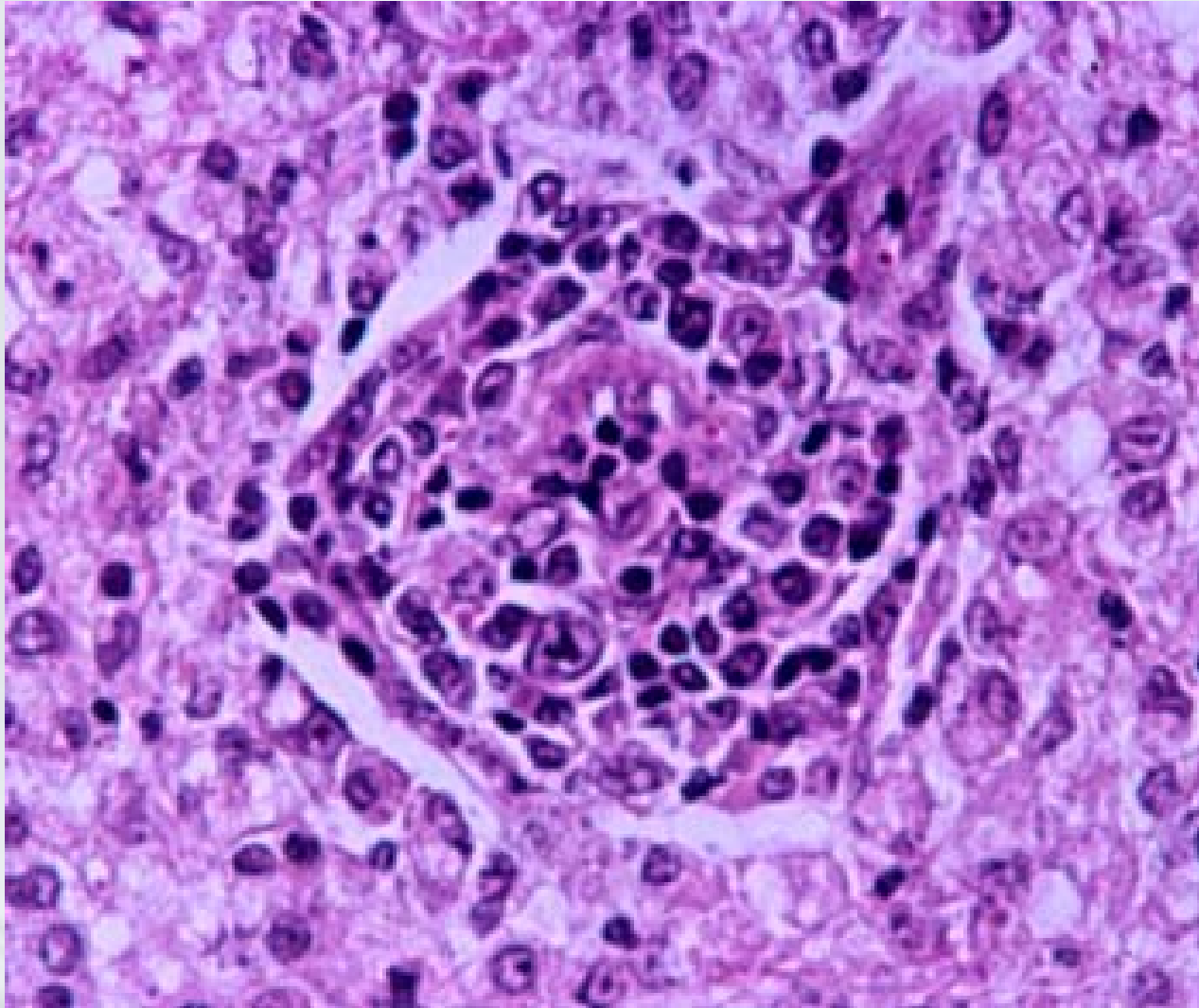
Carpal joint of a goat with caprine arthritis-encephalitis. The synovial membrane is thickened and has a villous surface



Synovial fluid and joint examination

- Histopathology reveals subsynovial infiltration with mononuclear cells and the presence of lymphoid follicles
- Synovial villus hypertrophy and focal areas of necrosis in the synovial membrane and/or the connective tissue surrounding the joint are often observed

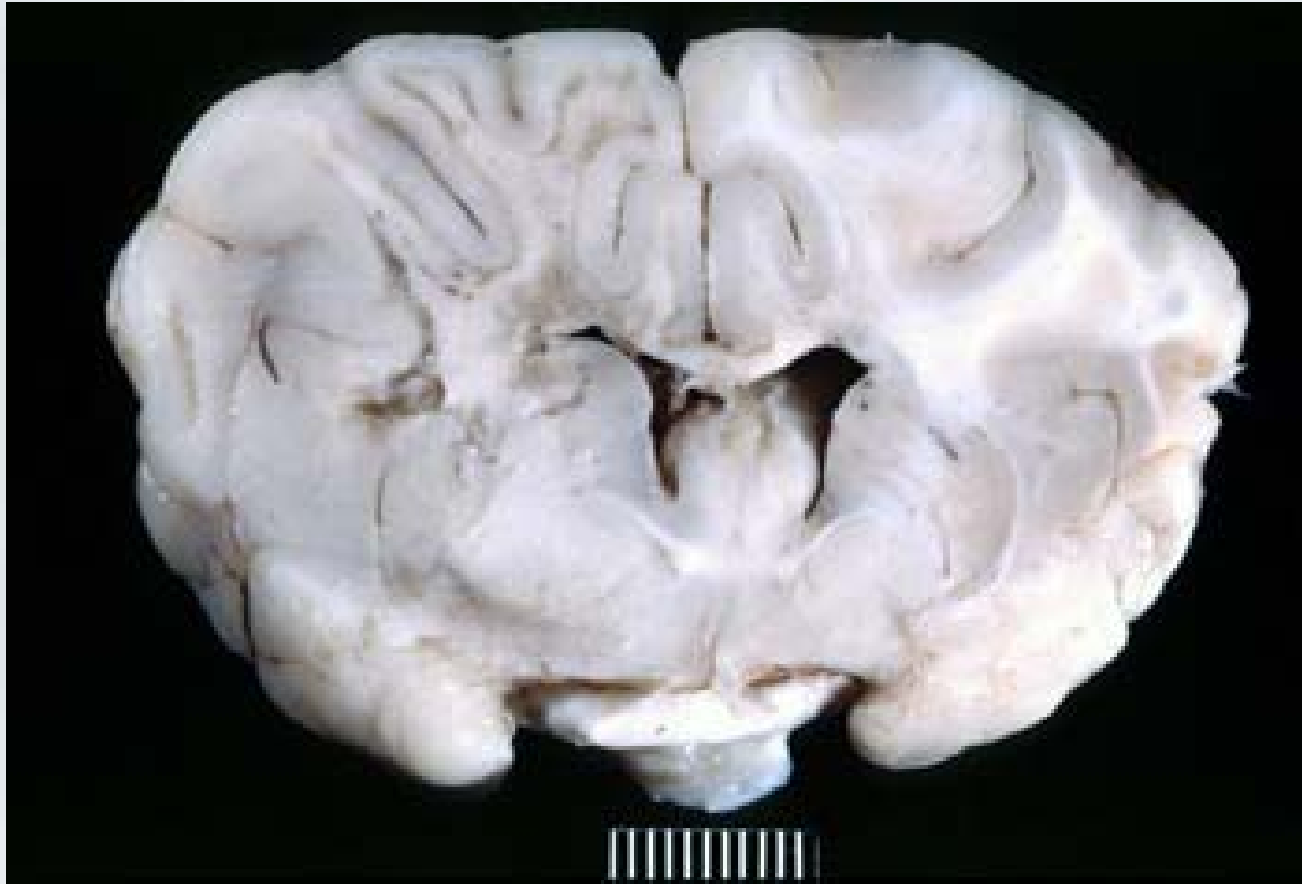
Synovial membrane of a goat with caprine arthritis-encephalitis.



CSF and CNS Tissue Evaluation

- With the encephalitic form of CAE viral infection, the CSF has an increased protein concentration with a mononuclear pleocytosis
- Post mortem examination may reveal asymmetrical, gray to pink foci of discoloration in the brain and/or spinal cord

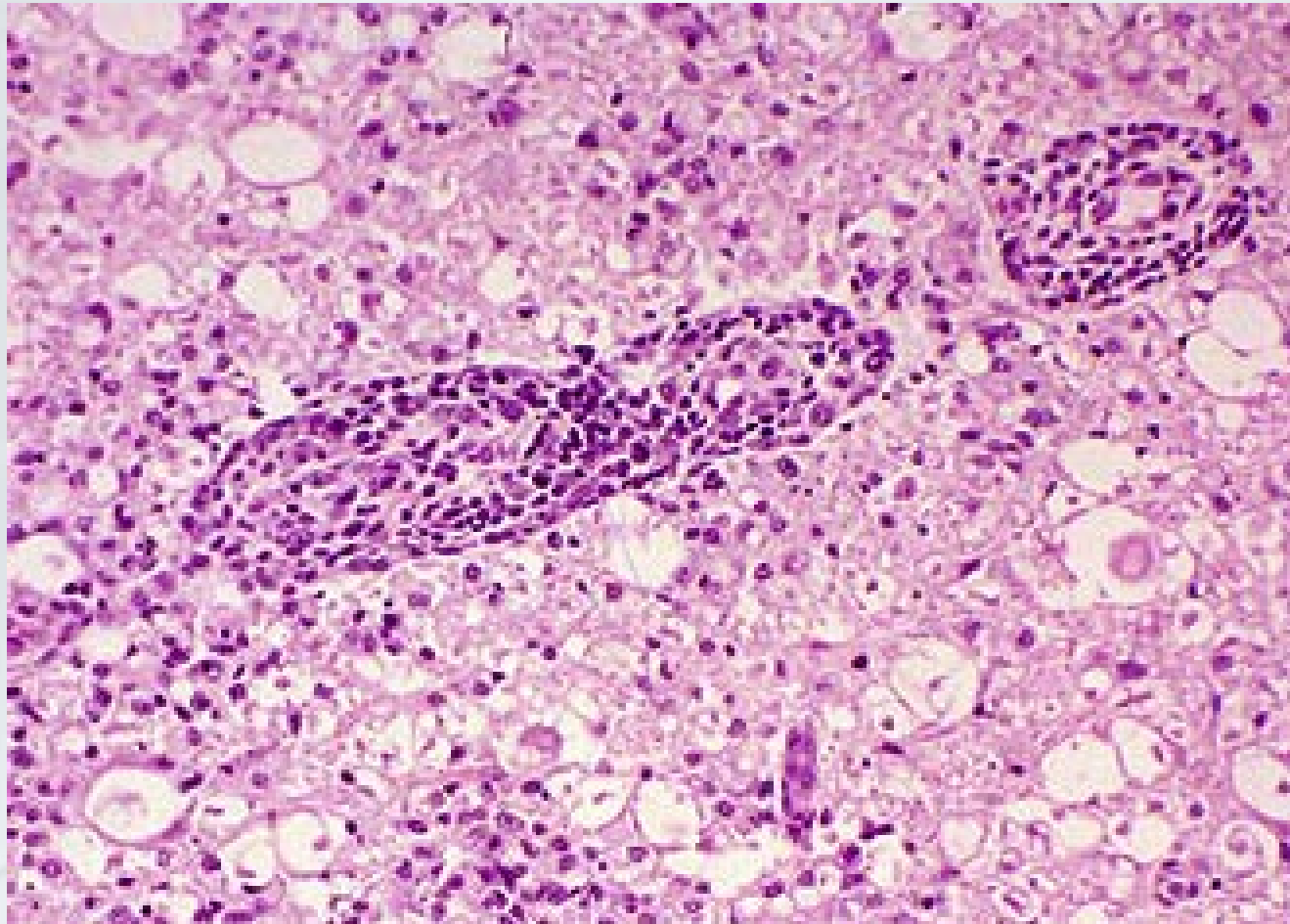
Cross section of the brain from a goat with caprine arthritis-encephalitis. Coagulative necrosis is present



CSF and CNS Tissue Evaluation

- Histopathology reveals widespread perivascular infiltration by mononuclear cells
- This infiltrate is composed of macrophages, lymphocytes, and plasma cells
- Coagulative necrosis and demyelination of the white matter also is observed; for this reason CAE previously was known as viral leukoencephalomyelitis

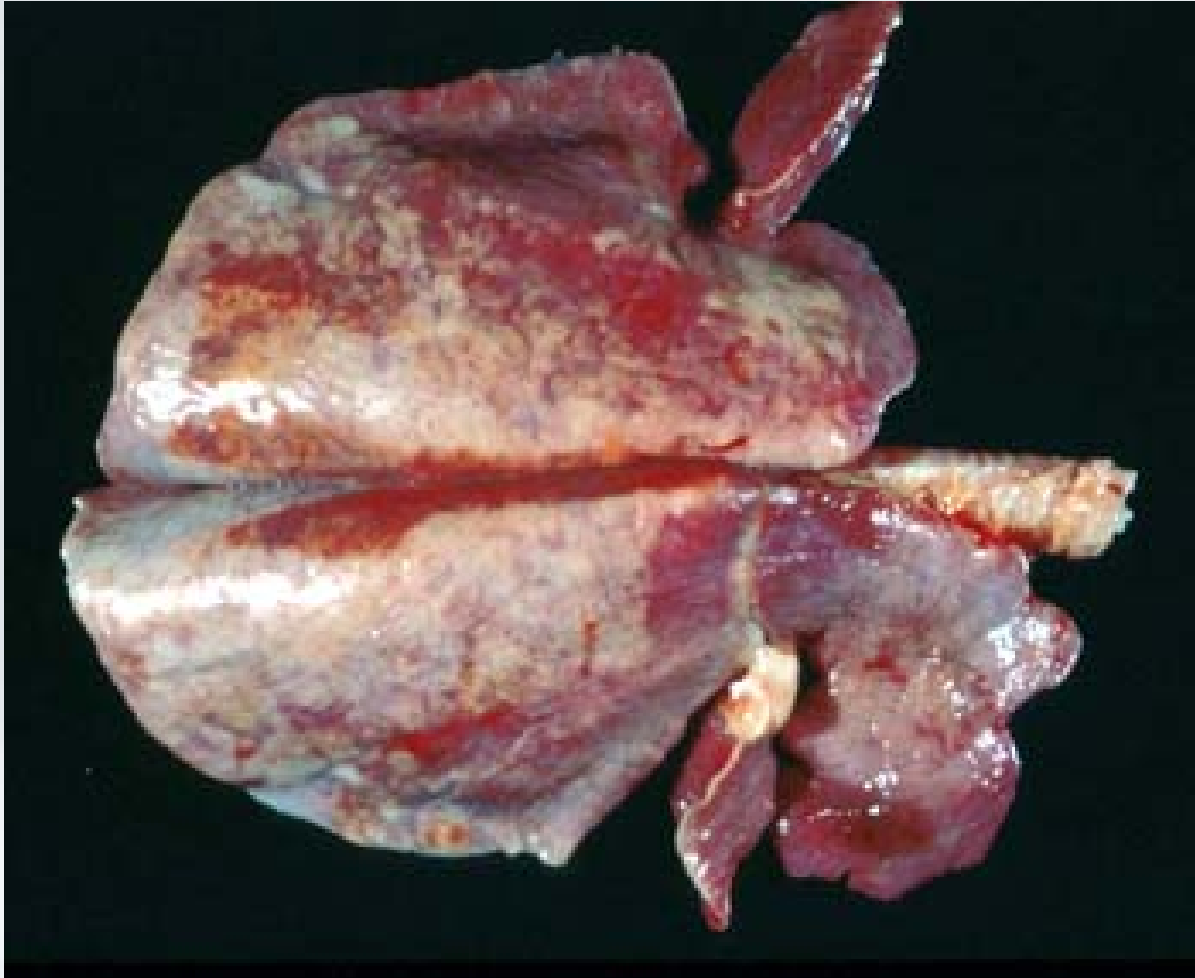Section of the brain from a goat with caprine arthritis-encephalitis. Perivascular infiltrates of mononuclear cells are present



Necropsy

- At necropsy, the cranioventral and/or caudal lung lobes are swollen in association with enlarged mediastinal lymph nodes
- Histopathology reveals nodular lymphoid aggregates, proliferation of smooth muscle, and massive infiltration of the alveolar walls by lymphoid cells

Swollen cranioventral lung lobes in a goat with caprine arthritis-encephalitis

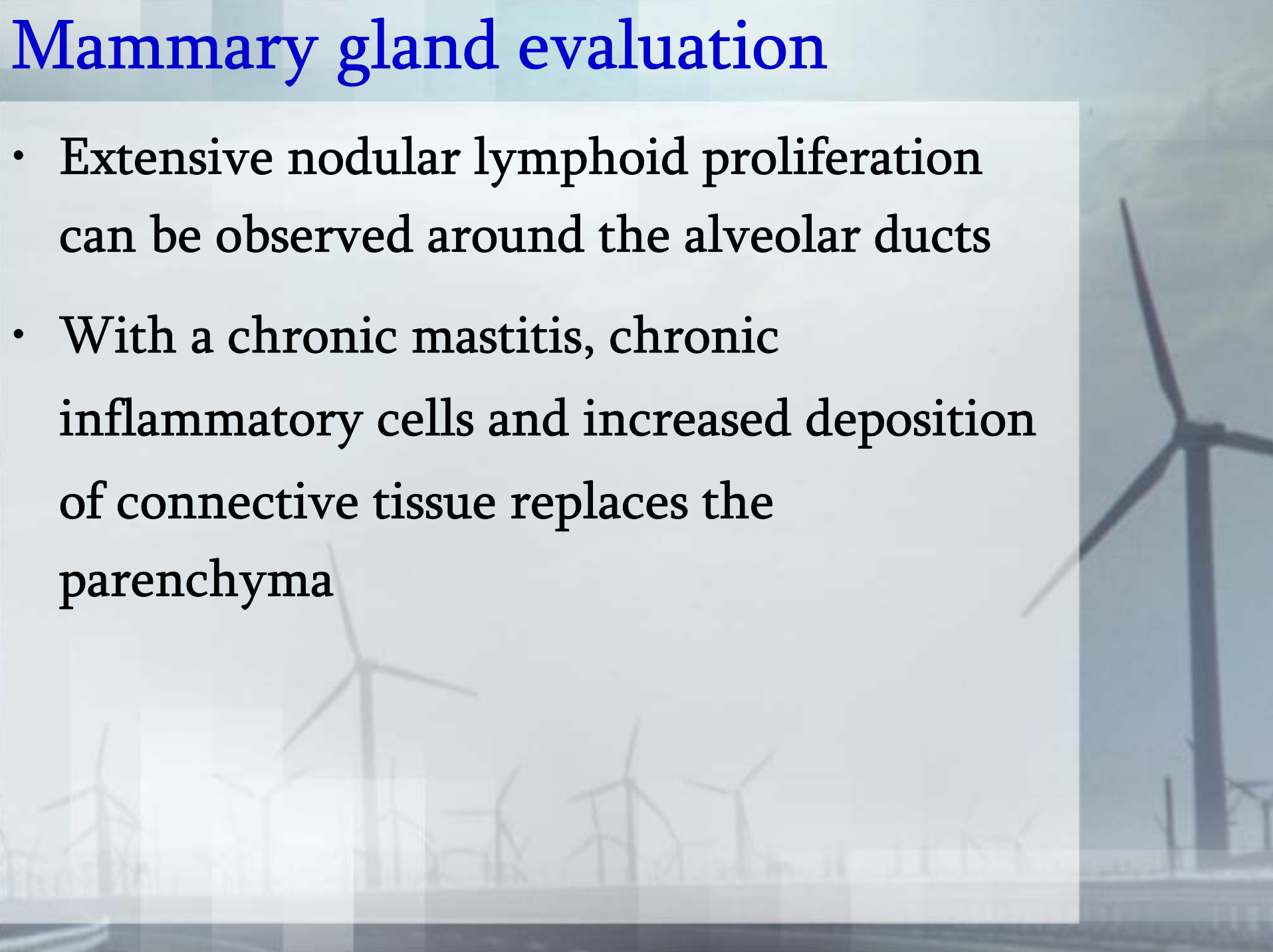


Mammary gland evaluation

- Because normal goat milk can contain large numbers of epithelial cells and macrophages, the interstitial mastitis caused by CAE viral infection is definitively diagnosed by histological examination
- Histopathology reveals foci of inflammatory cells within the interstitium

Mammary gland evaluation

- Extensive nodular lymphoid proliferation can be observed around the alveolar ducts
- With a chronic mastitis, chronic inflammatory cells and increased deposition of connective tissue replaces the parenchyma



Serological detection of anti-CAE Ab

- Serologic testing is a necessary and important component in diagnosing CAE. Most CAE-infected goats seroconvert within 3 to 12 weeks after viral exposure
- Antibody detection tests are used because, with a lentivirus infection, the animal is infected for life

Serological detection of anti-CAE Ab

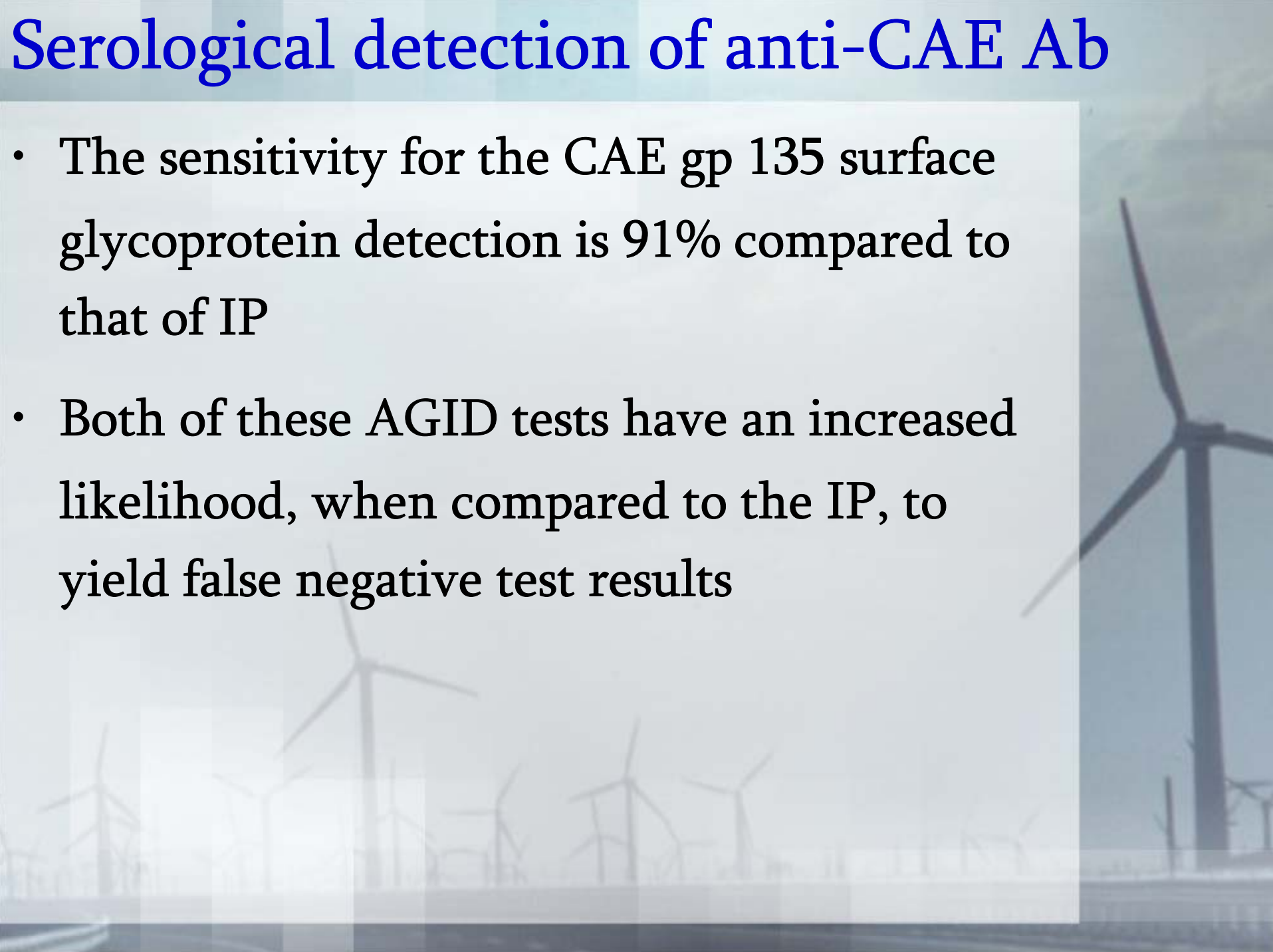
- The presence of antibodies indicates that the animal is infected with CAE virus.⁶
diagnostic tool
- The gold standard in testing for CAE antibodies is the immunoprecipitation assay (IP), but it is too expensive to use as a common

Serological detection of anti-CAE Ab

- The most widely used serologic test to detect anti-CAE antibody is the agar gel immunodiffusion test (AGID)
- Currently, there are two antigens that can be used in the AGID test, the CAE gp 135 surface glycoprotein and the less sensitive CAE p28 core protein
- The specificity for the AGID test is 100% when compared to the gold standard IP test

Serological detection of anti-CAE Ab

- The sensitivity for the CAE gp 135 surface glycoprotein detection is 91% compared to that of IP
- Both of these AGID tests have an increased likelihood, when compared to the IP, to yield false negative test results

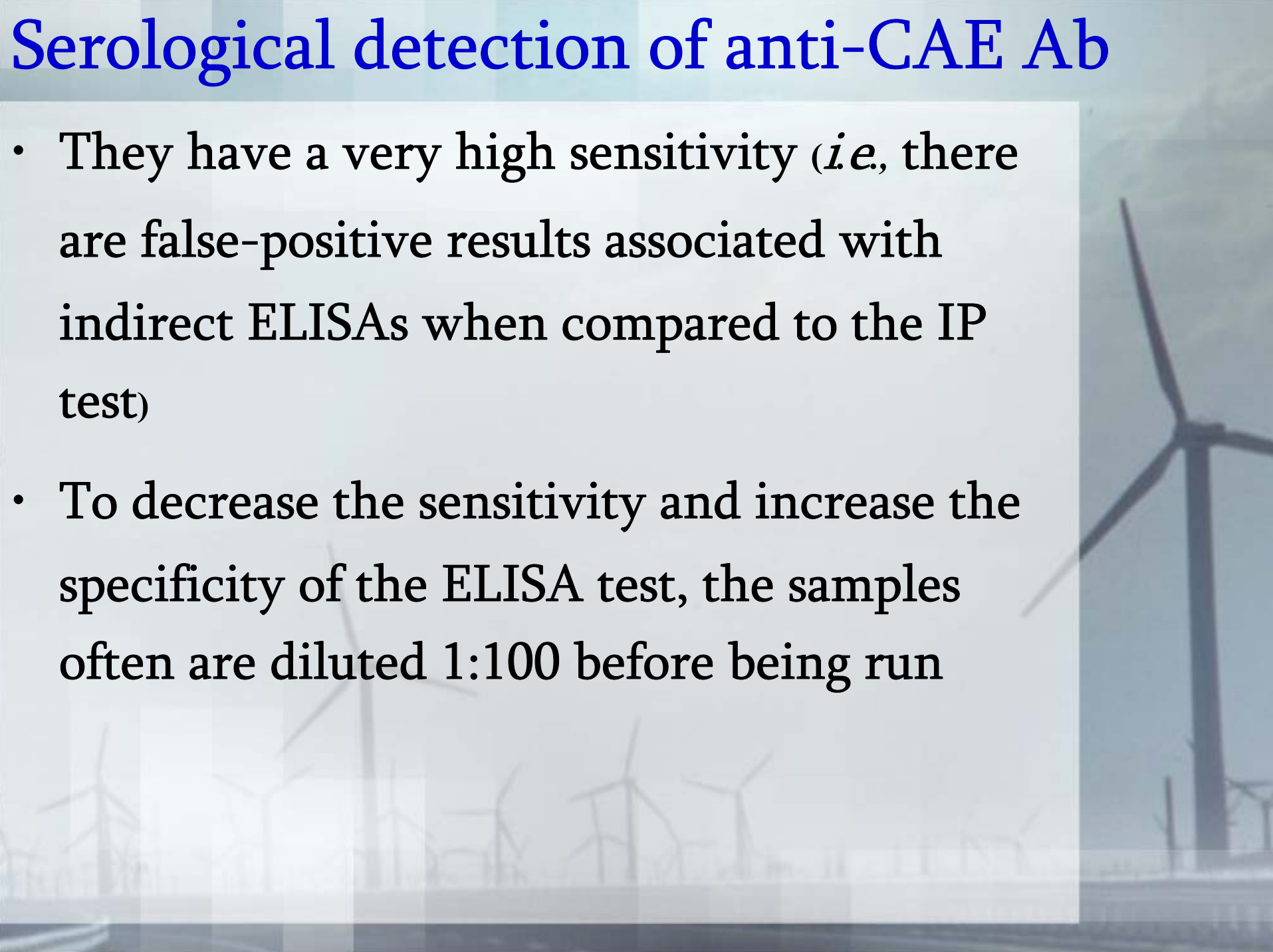


Serological detection of anti-CAE Ab

- Indirect enzyme linked immunosorbant assays (ELISA) are used to detect CAE antibodies in both the serum and milk
- However, the milk ELISA would not provide timely information to prevent the transfer of CAE virus in the colostrum and/or milk, the milk ELIAS is not widely used
- These ELISAs use recombinant and native viral antigens in to detect CAE antibodies

Serological detection of anti-CAE Ab

- They have a very high sensitivity (*i.e.*, there are false-positive results associated with indirect ELISAs when compared to the IP test)
- To decrease the sensitivity and increase the specificity of the ELISA test, the samples often are diluted 1:100 before being run



Serological detection of anti-CAE Ab

- There is a competitive ELISA (cELISA) that has just been developed to detect serum antibodies to CAE. The cELISA is more sensitive than the IP test in detecting CAE antibodies
- This can increase false-positive test results
- The cELISA can evaluate undiluted serum, thus detecting lower titers of anti-CAE antibody than the indirect ELISAs

Serological detection of anti-CAE Ab

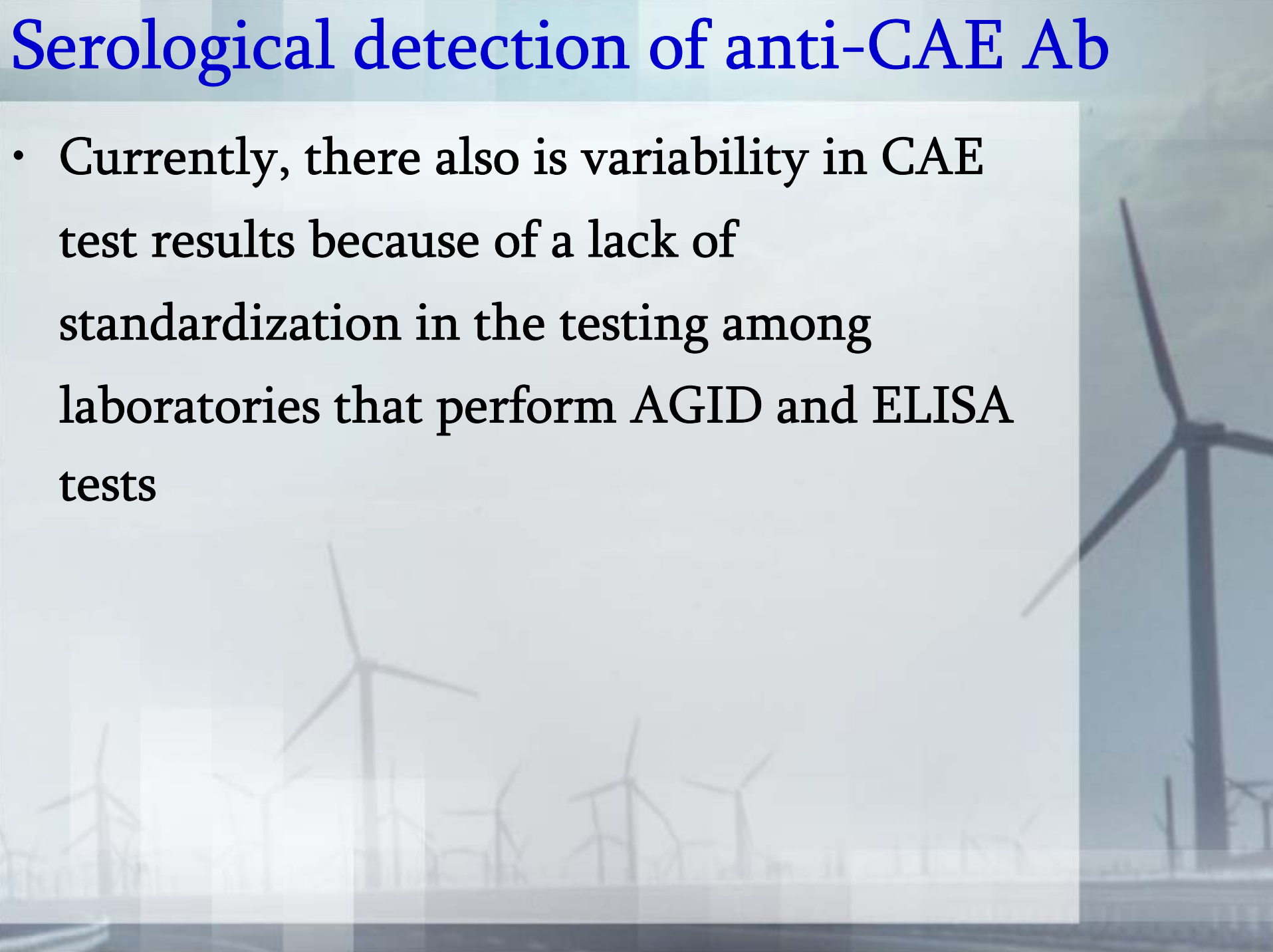
- This feature may possibly allow for the earlier detection of CAE positive animals
- If the serum is diluted when using the cELISA, the sensitivity of the test decreases
- This cELISA also may be able to detect antibodies in colostrum and milk samples

Serological detection of anti-CAE Ab

- Other methods of detecting CAE virus include the polymerase chain reaction (PCR) and virus isolation (VI)
- PCR can be used to detect CAE virus in milk and serum; however, PCR testing is not yet commercially available for the routine diagnosis of CAE
- VI has poor sensitivity and often takes 3 to 4 weeks to culture the virus

Serological detection of anti-CAE Ab

- Currently, there also is variability in CAE test results because of a lack of standardization in the testing among laboratories that perform AGID and ELISA tests



Treatments

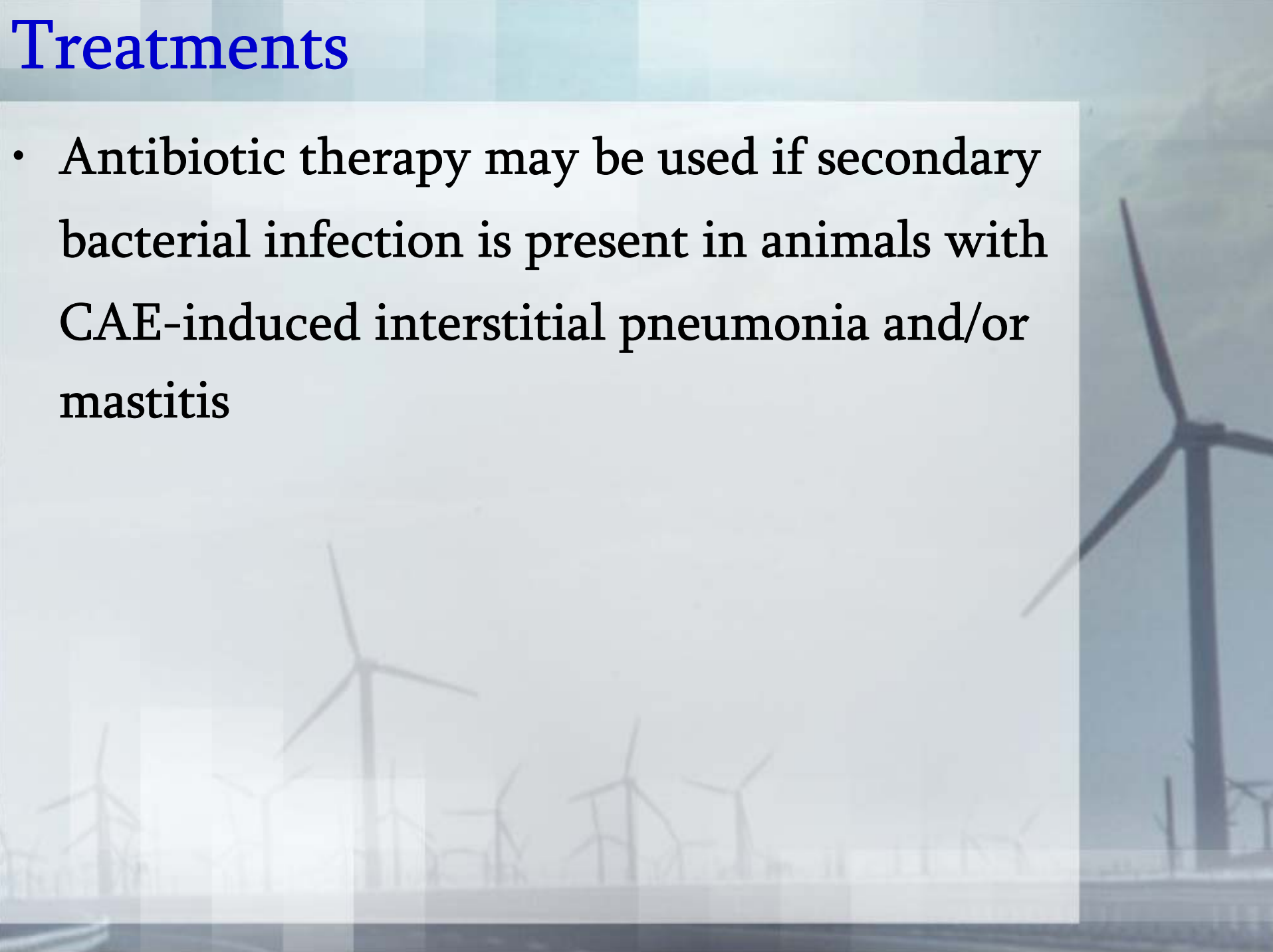
- The prognosis for the encephalitic form of CAE is poor, while the prognosis for the other four forms of disease is guarded
- There is no specific treatment for CAE
- Symptomatic therapy and supportive care have been used, but most affected animals are culled and/or euthanized because these animals are sources of infection and their clinical signs worsen over time

Treatments

- Current symptomatic therapy for the arthritic form of CAE includes frequent proper foot trimming, providing soft bedding, good pasture management, and administration of nonsteroidal anti-inflammatory drugs
- Physical therapy may be of benefit for recumbent kids with the encephalitic form of CAE

Treatments

- Antibiotic therapy may be used if secondary bacterial infection is present in animals with CAE-induced interstitial pneumonia and/or mastitis



Prevention

- Prevention of CAE viral infection is important in goat herd management because there is no treatment that eliminates CAE virus or vaccine to prevent this disease
- Most sources recommend maintaining a closed herd status
- Within the herd, all animals should be tested for CAE every 6 months beginning at 6 months of age

Prevention

- Seropositive individuals should be segregated and culled
- If culling is not an option, a variety of measures can be taken to minimize CAE viral transmission on the farm
- One measure is to remove kids from does immediately after birth to prevent any contact (including sniffing and licking) that may promote viral transmission

Prevention

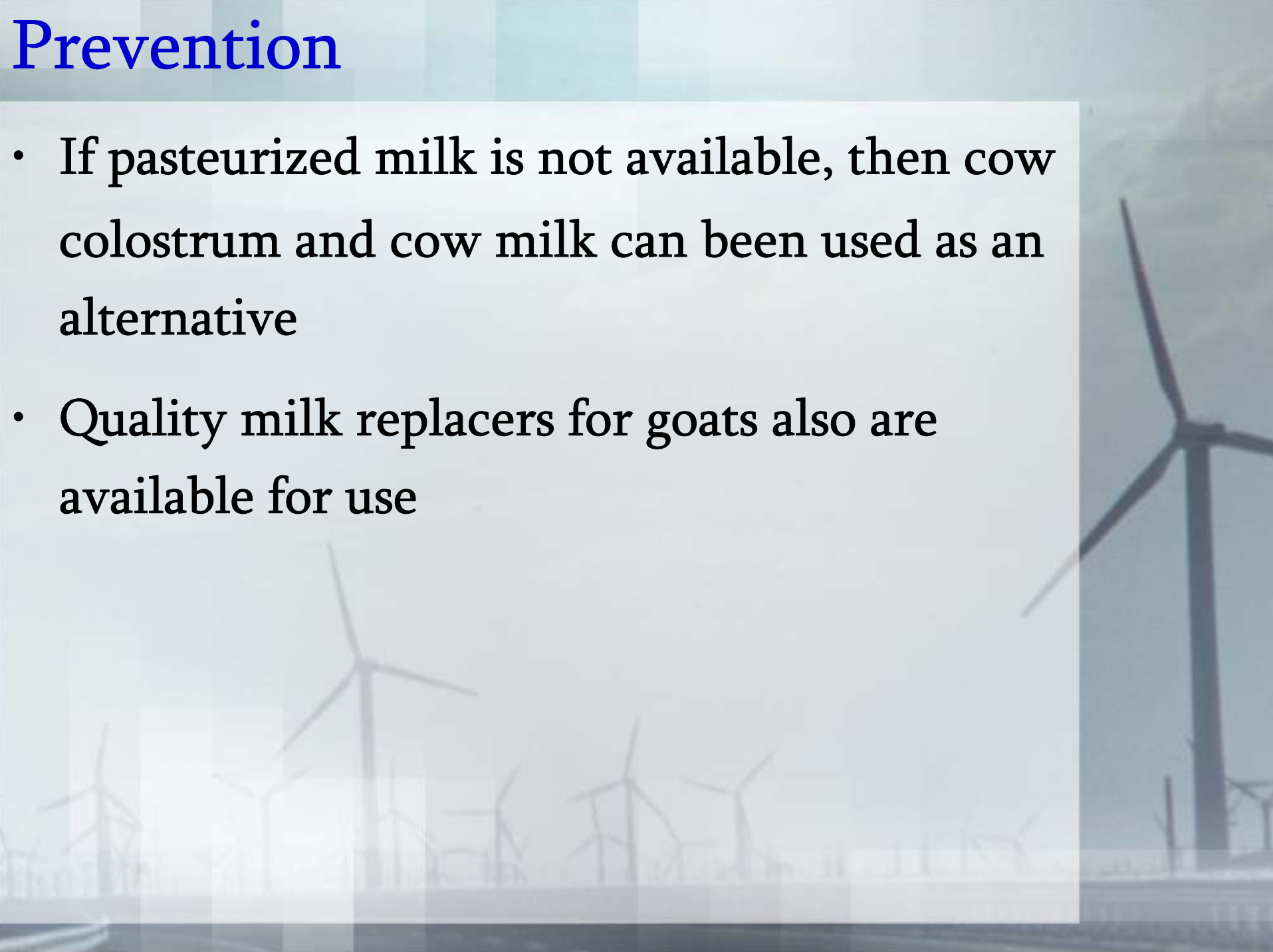
- Also, seropositive and seronegative does should be housed in separate pastures
- Kids born to seropositive does should be segregated from kids born to seronegative does until the CAE viral status of the kids can be determined

Prevention

- Kids should only be fed heat-treated/pasteurized goat colostrum and heat-treated/pasteurized goat milk
- To properly heat-treat colostrum, it should be heated at 56°C for one hour
- The virus is inactivated while the immunoglobulins remain intact

Prevention

- If pasteurized milk is not available, then cow colostrum and cow milk can be used as an alternative
- Quality milk replacers for goats also are available for use

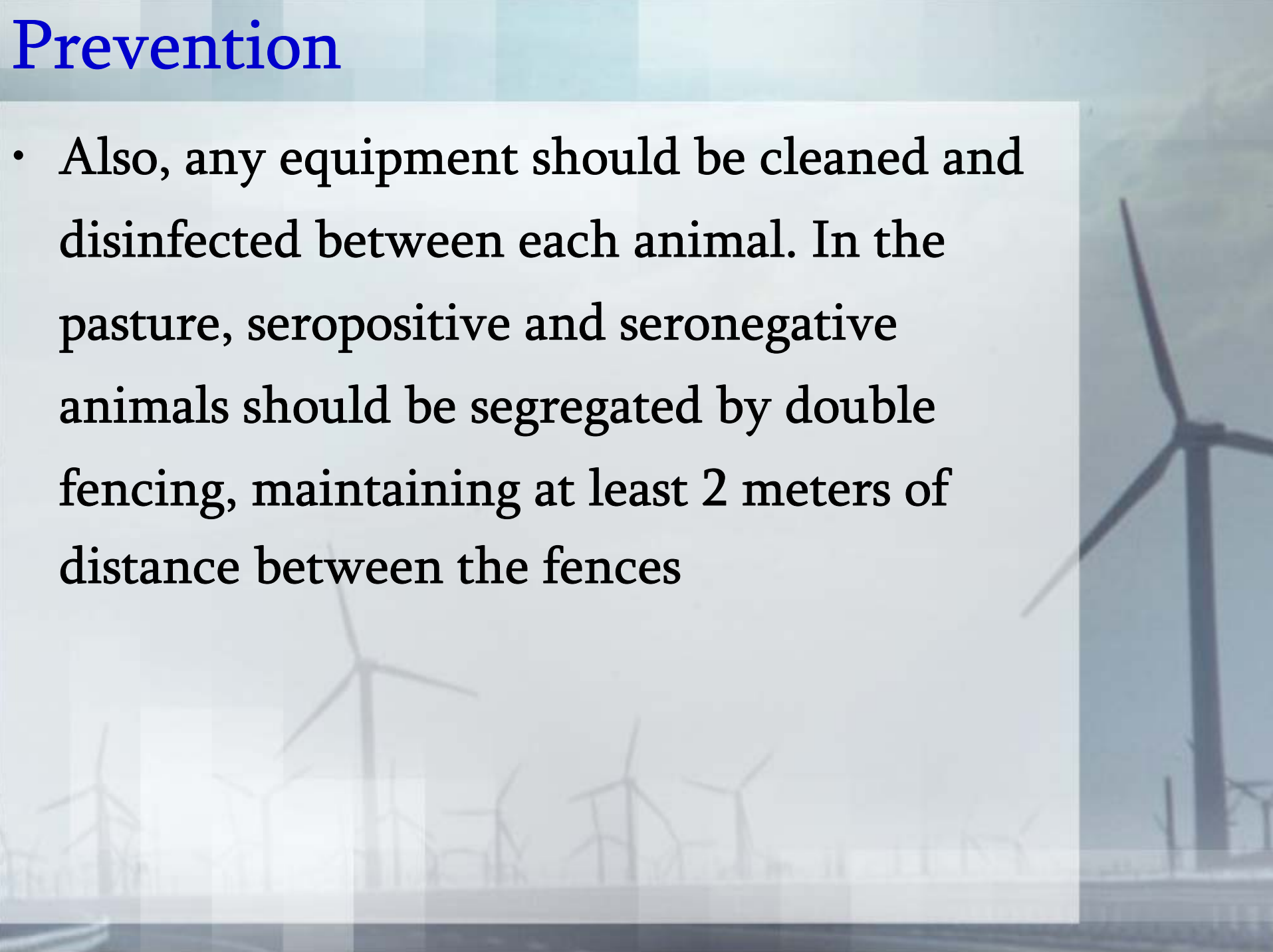


Prevention

- Seronegative animals should be milked first and the milking parlor should be disinfected after every milking
- Seropositive and seronegative animals should not be bred to each other
- Iatrogenic transmission of CAE virus should be avoided by using different instruments for seropositive and seronegative animals

Prevention

- Also, any equipment should be cleaned and disinfected between each animal. In the pasture, seropositive and seronegative animals should be segregated by double fencing, maintaining at least 2 meters of distance between the fences



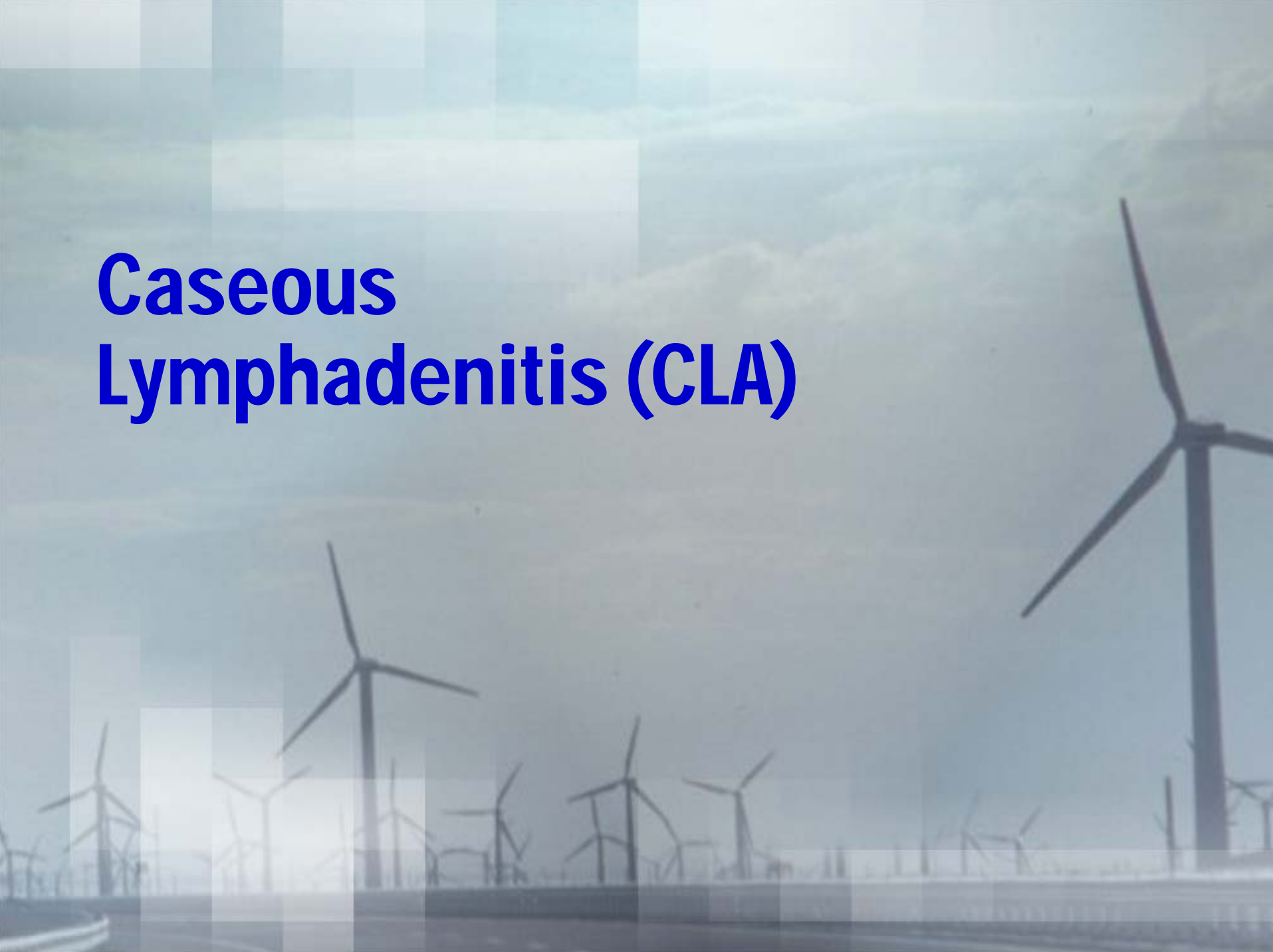Prevention

- Finally, if an open herd is maintained, goats should only be purchased from CAE virus-free herds
- New herd additions subsequently should be quarantined for at least 60 days and all animals should be CAE test-negative before adding them to the herd

Prevention

- Australia and New Zealand have established voluntary official accreditation programs to establish CAE-free goat herds
- Although the United States has no such program, goat herds exist that serologically test and cull any CAE-seropositive goats
- Such herds claim to have established a CAE-free goat herd status

Caseous Lymphadenitis (CLA)



Caseous lymphadenitis (CLA)

- Caseous Lymphadenitis (CLA) is a bacterial disease of chronic suppurative lymphadenitis of both sheep and goats that has major economic consequences
- It is commonly referred to as “Cheesy Gland” or “Lympho”, and is associated with “Thin Ewe Syndrome”

Etiology

- CLA is caused by *Corynebacterium pseudotuberculosis*. Abscessation of both internal and external lymph nodes is possible
- Goats tend to have abscessation of external lymph nodes, while sheep tend to have internal nodes affected

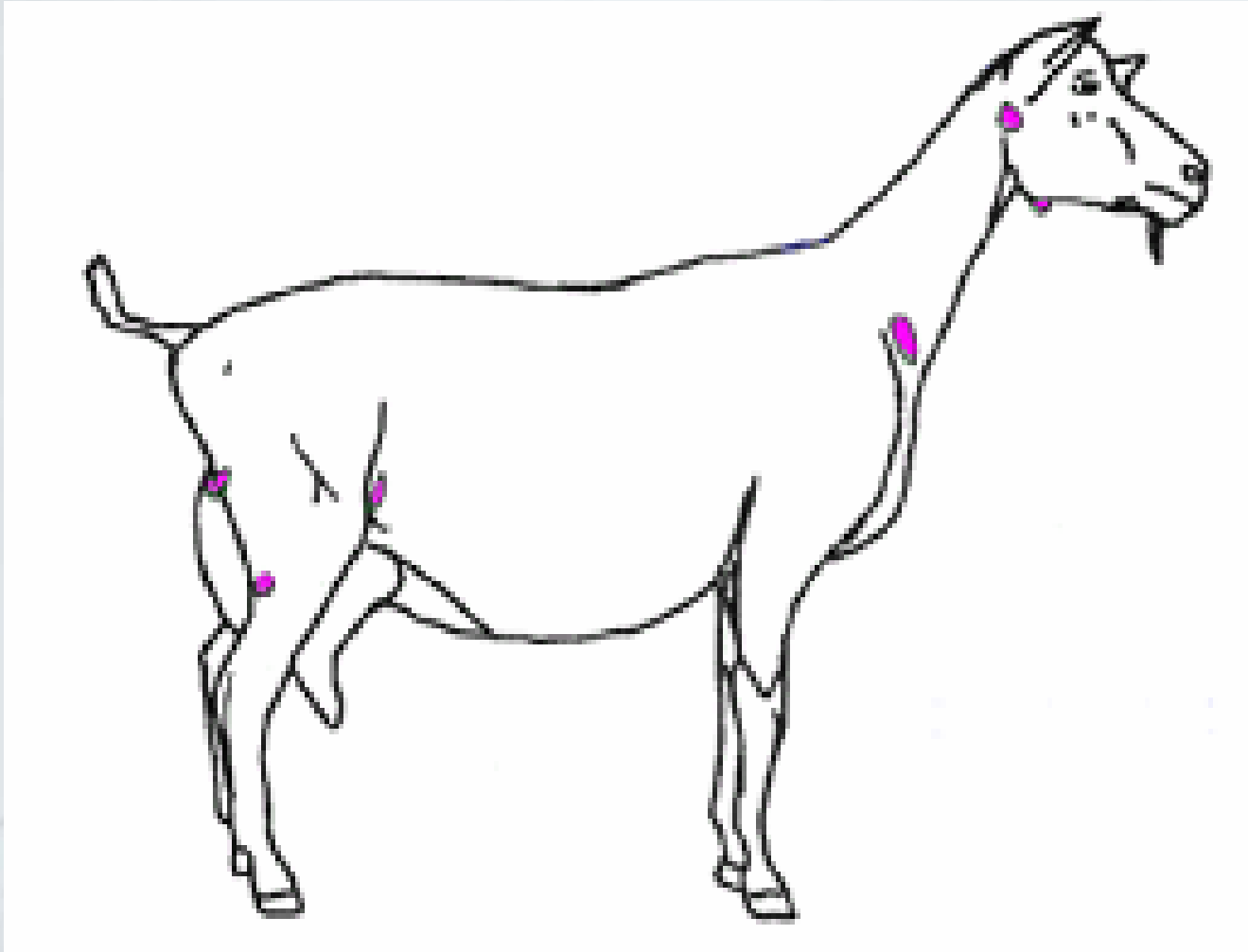
Etiology

- *C. Pseudotuberculosis* is a very short, Gram positive rod that may appear coccoid on a slide preparation
- A thick, flocculant, outer lipid layer makes the bacteria highly pyogenic and leads to thick-walled abscess formation
- *C. pseudotuberculosis* also produces an exotoxin that has more recently been a target for prevention

Etiology

- *C. pseudotuberculosis* can survive within purulent material in shaded areas on fence posts, in shearing barns, etc. for several months, and can be found in sheep feces, surviving in straw, hay, and wood for several weeks
- The bacteria can also survive at least 24 hours in commercial sheep dips

Location of common swellings caused by caseous lymphadenitis. Abscess in the location of external lymph nodes suggest caseous lymphadenitis



Clinical signs

- There are two basic forms that are typically recognized: an internal form and an external form
- It is likely that most infected animals are affected by both manifestations of the disease
- In the external form, most commonly recognized, obvious enlargement of the skin and peripheral lymph nodes can be appreciated, especially the reteropharyngeal, mandibular, parotid, prescapular, prefemoral, and popliteal lymph nodes

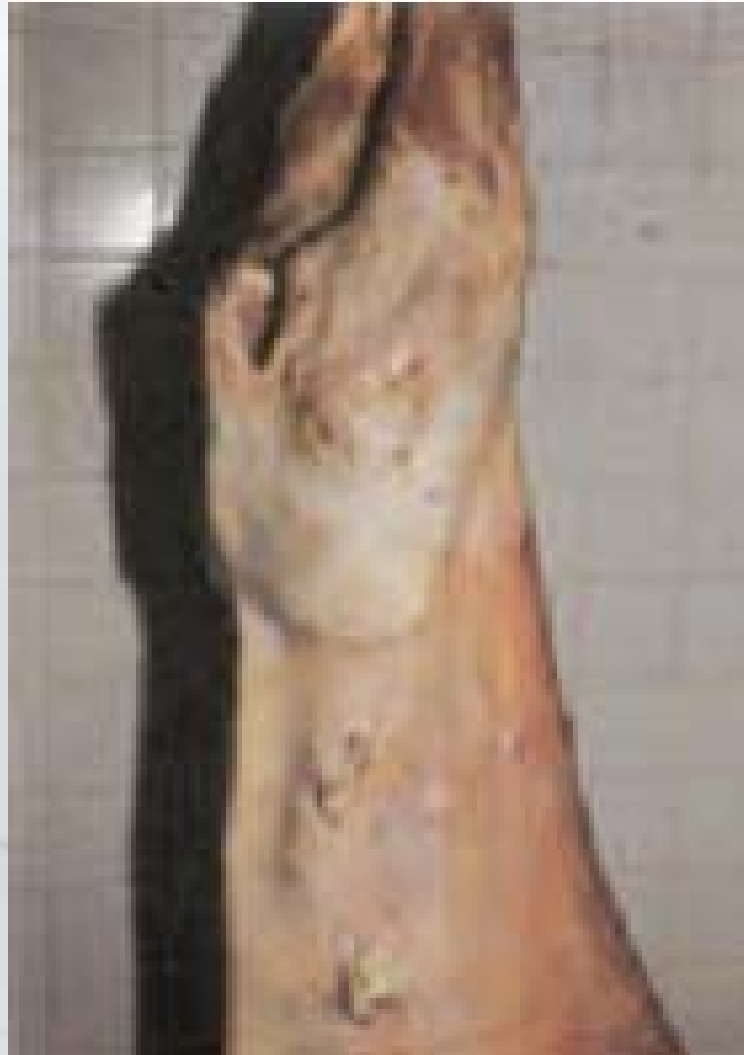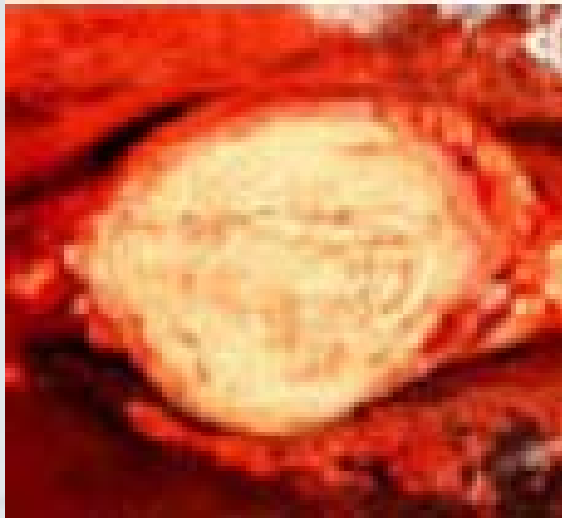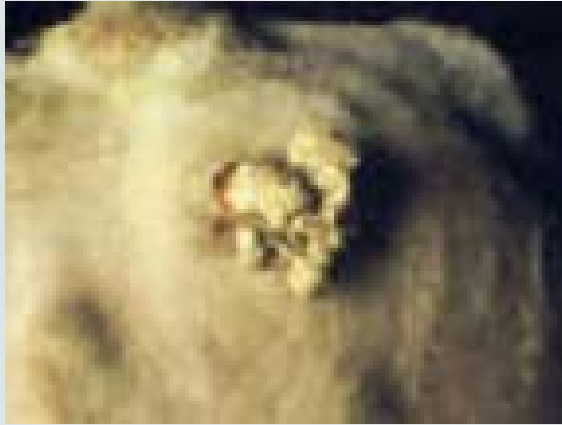
Clinical signs

- These lymph nodes and subcutaneous tissues are enlarged with thick, cheesy pus, and may rupture outward spontaneously or during shearing/dipping
- In both sheep and goats the pus within the abscesses is initially pale green, but in sheep it becomes thicker and forms onion-like rings, becoming a firm, calcified mass

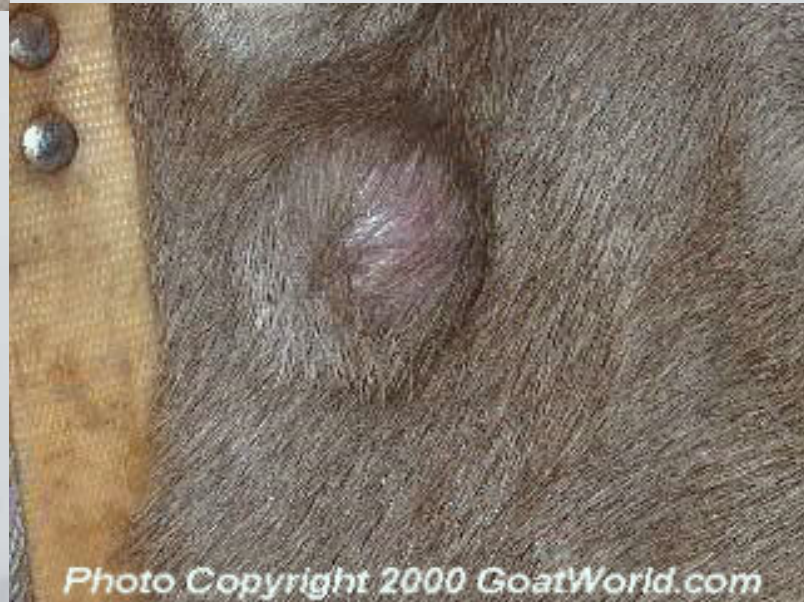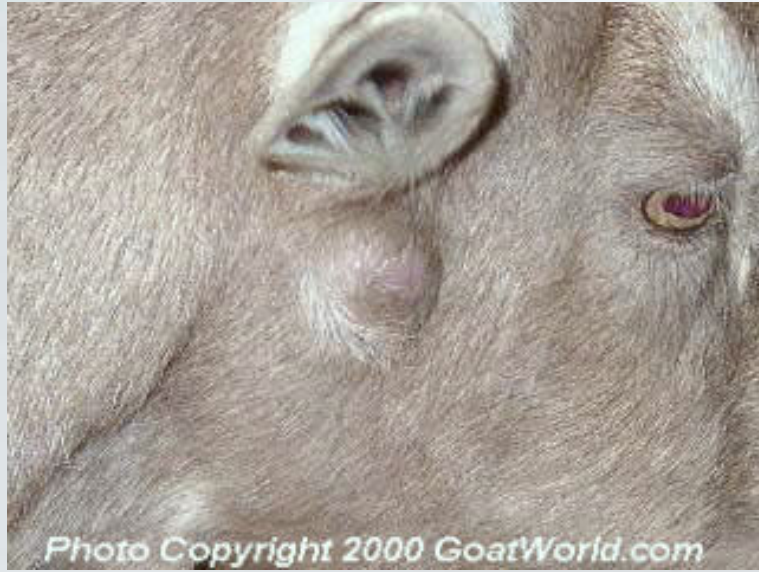Clinical signs

- If the internal form is present, affected animals show weight loss and poor productivity with decreased fertility, and decreased milk production
- They may exhibit mastitis, respiratory distress, chronic cough, or neurologic deficits, depending on the location of internal abscessation

Caseous lymph nodes



Caseous lymph nodes



Pathogenesis

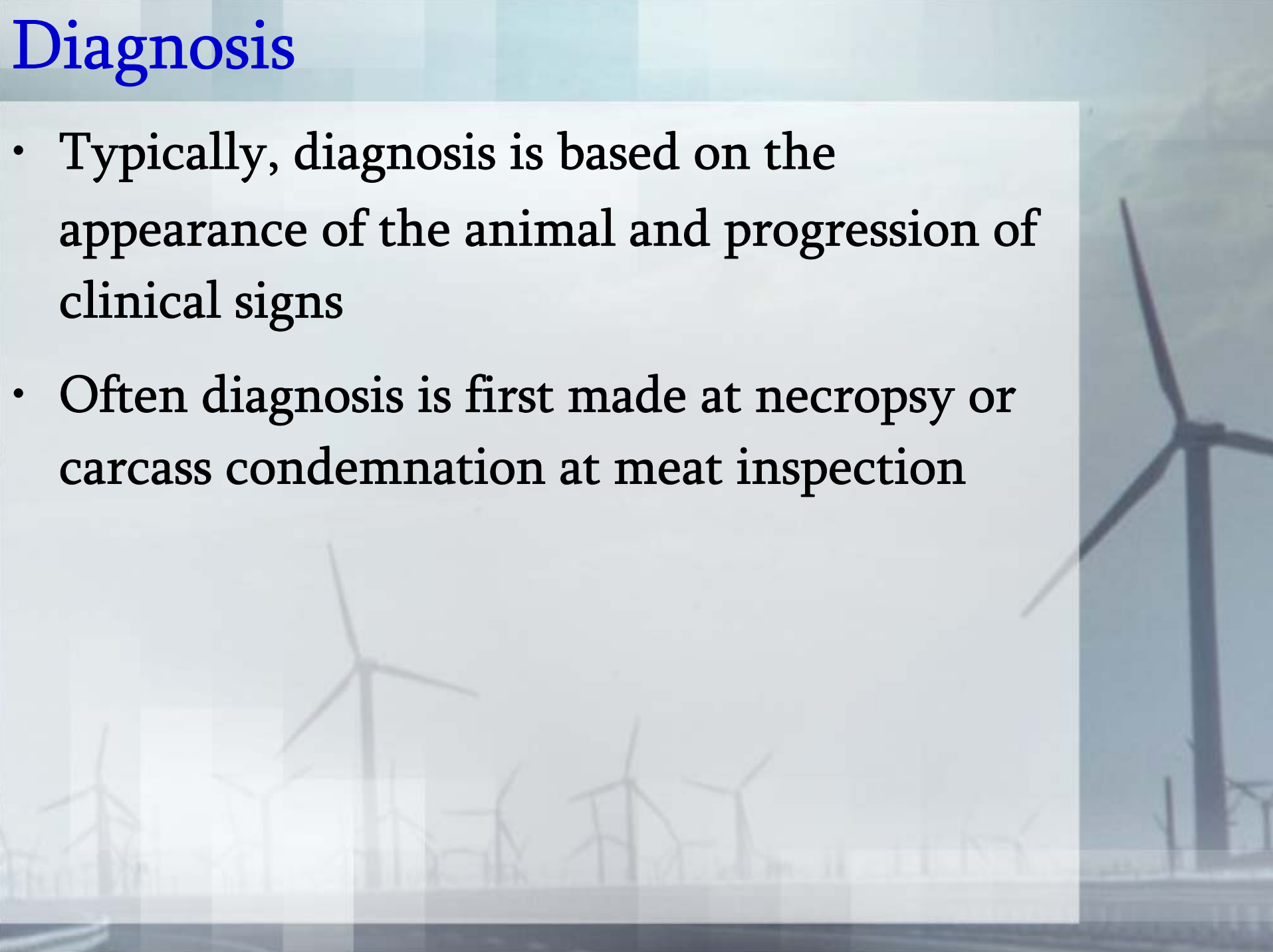
- The pathogenesis of CLA begins with the infection of a superficial wound often incurred at shearing
- The bacteria spread to the regional lymph node where they can progress to other nodes or internal organs through the lymphatics or vasculature
- The onion-like appearance on cross-section of involved lymph nodes is due to stages of necrosis and capsule formation of the abscess

Pathogenesis

- *C. pseudotuberculosis* is an intracellular parasite of monocytes and macrophages, the cells that are responsible for engulfing and digesting bacteria and debris
- *C. pseudotuberculosis* bacteria are able to survive within these phagocytic cells and multiply, then kill the cell, allowing dissemination of more bacteria
- New macrophages phagocytose the bacteria and the process is repeated

Diagnosis

- Typically, diagnosis is based on the appearance of the animal and progression of clinical signs
- Often diagnosis is first made at necropsy or carcass condemnation at meat inspection



Diagnosis

- If draining tracts are identified *C. pseudotuberculosis* organisms can be cultured but are difficult to grow on blood agar plates
- Several serological tests have been developed including the hemolysis inhibition test, an ELISA test and an agar gel immunoprecipitation test

Prevention

- Historically CLA has been controlled in herds by culling visibly infected animals and emphasizing hygiene in shearing and handling animals
- These methods are effective in reducing the incidence of disease on a farm, and should continue to be implemented.

Prevention

- There are several points of attention for maintaining good hygiene
- Preventing wounds by careful blade shearing, maintaining good fencing, and the use of well trained, gentle-mouthed dogs for herding can all reduce the incidence of wounding

Prevention

- Decreasing the infection of wounds by quickly moving animals from higher contamination areas, disinfection of clipper blades and shearing equipment, construction of easily cleanable shearing sheds, and avoidance of dipping sheep until after all wounds have healed may all decrease infection
- Shearing sheep youngest to oldest may also help prevent infection of uninfected animal

Prevention

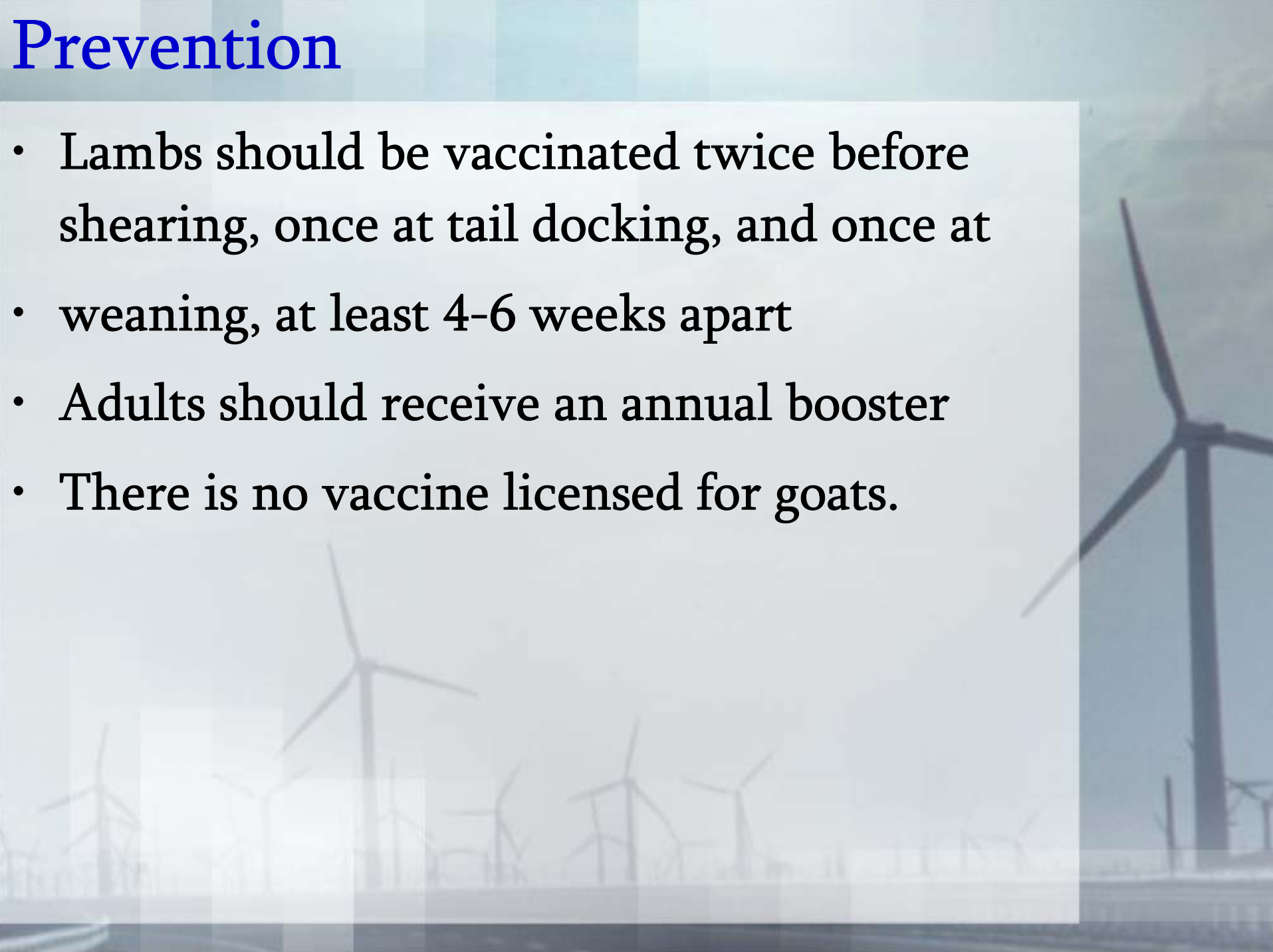
- Vaccination of sheep and goats can reduce the severity of CLA
- Older vaccines provided partial protection and contained inactivated whole-cell, cell-wall extract, or inactivated exotoxin
- Newer vaccines contain both inactivated whole cell antigen and detoxified exotoxin
- The newer two-component vaccine has been shown to decrease both the number of abscesses in sheep and the number of sheep that develop abscesses

Prevention

- Further, there was a significant reduction of both internal and external abscesses leading to fewer condemned carcasses and reduced environmental contamination and subsequent spread of disease
- The vaccine should not be used in naive flocks/herds
- Vaccinated animals will have a positive serological test result, indistinguishable from infected animals

Prevention

- Lambs should be vaccinated twice before shearing, once at tail docking, and once at weaning, at least 4-6 weeks apart
- Adults should receive an annual booster
- There is no vaccine licensed for goats.



Prevention

- Additionally, all new animals should be carefully inspected for peripheral lymph node enlargement, draining tracts, or other evidence of disease
- If possible animals should be purchased from known CLA-free herds.